



## RESEARCH ARTICLE

## EFFICACY OF METHANOL EXTRACT OF *OCIMUM GRATISSIMUM* IN MODULATING PROSTATE SIZE, ANTIOXIDANT ACTIVITY, AND HISTOPATHOLOGY IN TESTOSTERONE INDUCED BENIGN PROSTATE HYPERPLASIA IN MALE ALBINO RATS

Prince Ogochukwu Alaabo<sup>1</sup> , Chinedu Paulinus Nwuke<sup>1</sup> , Ngozi Kalu Achi<sup>1</sup> ,  
 Precious Ulonnam Ezuruike<sup>1</sup> , Anthony Cemaluk Chinedum Egbuonu<sup>1</sup> , Enyinna Wisdom  
 Chukwuka<sup>1</sup> , Favour Junior Abuchi<sup>1</sup> , Anthony Uchenna Onochie<sup>2</sup> 

<sup>1</sup>Department of Biochemistry, College of Natural Sciences, Michael Okpara University of Agriculture, Umudike, P. M. B. 7267. Umuahia, Abia State, Nigeria.

<sup>2</sup>Department of Biochemistry, Faculty of Natural Sciences, Chukwuemeka Odumegwu Ojukwu University, Uli. P. M. B. 6059. Anambra, State, Nigeria.

## Article Info:



## Article History:

Received: 11 December 2024

Reviewed: 6 January 2025

Accepted: 14 February 2025

Published: 15 March 2025

## Cite this article:

Alaabo PO, Nwuke CP, Achi NK, Ezuruike PU, Egbuonu ACC, Chukwuka EW, Abuchi FJ, Onochie AU. Efficacy of methanol extract of *Ocimum gratissimum* in modulating prostate size, antioxidant activity, and histopathology in testosterone induced benign prostate hyperplasia in male albino rats. Universal Journal of Pharmaceutical Research 2025; 10(1): 25-30. <http://doi.org/10.22270/ujpr.v10i1.1270>

## \*Address for Correspondence:

Prince Ogochukwu Alaabo, Department of Biochemistry, College of Natural Sciences, Michael Okpara University of Agriculture, Umudike, P.M.B. 7267. Umuahia, Abia State, Nigeria. Tel: +234 8064481954; E-mail: [alaabo.prince@mouau.edu.ng](mailto:alaabo.prince@mouau.edu.ng)

## Abstract

**Background:** Benign Prostatic Hyperplasia (BPH) is a common condition in aging men, caused by the non-cancerous enlargement of the prostate, frequently linked to oxidative stress and impaired prostate function.

**Aim:** This study evaluates the effectiveness of methanol extract of *Ocimum gratissimum* in modulating pathological markers in testosterone-induced BPH in male wistar rats.

**Methods:** A total of 36 rats were allocated into six experimental groups: normal control, BPH control (testosterone-induced), and four treatment groups receiving different doses of *Ocimum gratissimum* extract (200, 400, and 600 mg/kg) and a standard treatment (finasteride, 5 mg/kg). BPH was induced by administering subcutaneous testosterone propionate (3 mg/kg) for 14 days.

**Results:** The results revealed that the extract significantly reduced prostate size and weight in a dose-dependent manner. Additionally, *Ocimum gratissimum* extract demonstrated potent antioxidant effects by increasing catalase (CAT) activity and decreasing malondialdehyde (MDA) levels, markers of oxidative stress, in comparison to the BPH control group. The extract also improved serum lipid profiles, with significant reductions in total cholesterol, triglycerides, and low-density lipoprotein cholesterol (LDL-C) reduction, while enhancing high-density lipoprotein cholesterol (HDL-C) levels and histopathological improvements, including reduced inflammation and hyperplasia.

**Conclusions:** The findings support the therapeutic potential of *Ocimum gratissimum* in managing BPH by alleviating prostate enlargement, improving antioxidant defenses, reducing oxidative stress, and modulating lipid profiles. The results suggest that *Ocimum gratissimum* may offer a natural alternative or adjunct to conventional therapies for managing BPH and related complications. Further research is needed to investigate the underlying mechanisms of action.

**Keywords:** Antioxidant activity, benign prostatic hyperplasia, histopathology, *Ocimum gratissimum*, testosterone.

## INTRODUCTION

Benign Prostatic Hyperplasia (BPH) is a prevalent condition among aging men, characterized by the non-cancerous enlargement of the prostate gland<sup>1,2</sup>. This condition can cause various lower urinary tract symptoms, such as urinary retention, nocturia, and weak urine flow, significantly affecting the quality of life<sup>3</sup>. The pathophysiology of BPH is driven by an

imbalance between prostate cell growth and apoptosis, primarily influenced by hormonal factors like dihydrotestosterone (DHT) and estrogen<sup>4</sup>.

Testosterone, a key hormone in prostate enlargement, is converted to DHT by the enzyme 5-alpha reductase, which plays a crucial role in BPH development<sup>5</sup>. Furthermore, oxidative stress has been linked to BPH progression, contributing to tissue damage and intensifying inflammation in the prostate<sup>6,7</sup>.

Current pharmacological management of BPH involves the use of alpha-blockers and 5-alpha reductase inhibitors (e.g., finasteride), are effective in reducing symptoms but often come with adverse effects such as sexual dysfunction, dizziness, and fatigue<sup>8</sup>. As a result, there has been growing interest in exploring natural alternatives with fewer side effects, such as herbal medicines. *O. gratissimum*, commonly known as Nigerian basil or scent leaf, is a plant with a broad spectrum of pharmacological effects, including antioxidant, anti-inflammatory, and antimicrobial properties<sup>9</sup>. Recent studies have highlighted its potential in modulating oxidative stress and inflammation, which are central to the pathogenesis of BPH<sup>9</sup>. Furthermore, *O. gratissimum* has been reported to possess several bioactive compounds, including flavonoids, tannins, saponins, and essential oils, which contribute to its therapeutic effects<sup>10</sup>.

This study seeks to assess the effectiveness of the methanol extract of *O. gratissimum* on prostate size and weight, histopathological alterations, antioxidant enzyme activities (such as catalase), and oxidative stress markers (malondialdehyde, MDA) in a testosterone-induced BPH model in male albino rats. The hypothesis is that *O. gratissimum* extract can attenuate the enlargement of the prostate and the associated oxidative stress in BPH, providing a potential therapeutic alternative to conventional treatments.

## MATERIALS AND METHODS

**Plant collection:** Fresh *O. gratissimum* leaves were sourced from Ore-Ugba Market in Abia State, Eastern Nigeria, and authenticated by Prof. Garuba Omotosun from the Department of Plant Science and Biotechnology, College of Natural Sciences, Michael Okpara University of Agriculture, Umudike. Following collection, the leaves were thoroughly washed with distilled water to eliminate contaminants, and then air-dried at room temperature. Once dried, they were ground into a fine powder using an automated milling machine, yielding a total weight of 200 g, as measured with an analytical weighing scale.

**Experimental animals:** Thirty-five (35) male Wistar rats weighing 110–150 g were utilized in this study. The animals were obtained from Dr. Daniel's Animal House in the Veterinary Medicine Animal House, Michael Okpara University of Agriculture, Umudike, Abia State. Prior to the experiment, the rats were acclimatized to laboratory conditions for two weeks under standard housing conditions, with unrestricted access to food and water. They were housed in groups of five in standard cages, maintained under a 12-hour light/dark cycle.

### Experimental design

The animals were randomly assigned into six experimental groups (n = 6 per group) as follows:

**Group 1:** Normal control (no treatment was administered)

**Group 2:** BPH-induced negative control (untreated)

**Group 3:** Positive control (administered a standard drug)

**Groups 4, 5, and 6:** Treatment groups receiving methanol extract of *O. gratissimum* at doses of 200 mg/kg, 400 mg/kg, and 600 mg/kg body weight, respectively.

Benign Prostatic Hyperplasia (BPH) was induced by daily subcutaneous administration of testosterone propionate (3 mg/kg body weight) for 14 days. Following BPH induction, treatment with the methanol extract was initiated and continued for 28 days. Throughout the experimental period, each group was monitored for changes in body weight, prostate size, and behavior. Upon completion of the treatment phase, the rats were sacrificed, and blood samples were obtained for serum prostate-specific antigen (PSA) and oxidative stress marker analysis. Prostate tissues were excised, weighed, and analyzed through histopathological examination.

**Ethical consideration:** The experimental protocol adhered to ethical guidelines set by the National Research Council (NRC) of the USA. The procedures for animal sacrifice and determination of biochemical markers, such as serum potassium and kidney malondialdehyde, followed the protocols outlined by Sinha<sup>11</sup>.

**Induction of BPH:** BPH was induced in the rats through the administration of testosterone propionate (3 mg/kg body weight) subcutaneously daily for 14 days. This induction protocol was selected based on previous studies demonstrating effective induction of BPH in rats<sup>12</sup>.

**Collection of blood samples and biochemical analysis:** At the conclusion of the treatment period, blood samples were obtained via retro-orbital puncture. The serum was separated by centrifugation at 3000 rpm for 10 minutes and stored at -20°C for subsequent biochemical analyses, including prostate-specific antigen (PSA) and oxidative stress markers.

**Measurement of prostate size and weight:** Following euthanasia, the prostate glands were excised, and their size and weight were measured and compared among the groups. Prostate weights were recorded using an analytical balance, and prostate sizes were determined by measuring the length, width, and height of the glands.

### Biochemical Analysis

**Measurement of Malondialdehyde:** Malondialdehyde (MDA) levels in serum and prostate tissues were assessed as a marker of lipid peroxidation using the thiobarbituric acid reactive substances (TBARS) assay, following the method described by Ohkawa *et al.*<sup>13</sup>. The analysis involved homogenizing prostate tissues in phosphate-buffered saline (PBS) and centrifuging the mixture at 3000 rpm. The obtained supernatant was then combined with sodium dodecyl sulfate, acetic acid, and thiobarbituric acid, followed by heating at 95°C for 60 minutes. The final reaction product was quantified spectrophotometrically at 532 nm.

**Measurement of Catalase Activity (CAT):** Catalase activity was assessed following the procedure described by Aebi<sup>14</sup>. The breakdown of hydrogen peroxide was tracked spectrophotometrically at 240 nm. The activity of catalase was reported in units per milligram of protein.

### Measurement of serum lipid profile

The serum lipid profile is assessed using commercially available enzymatic kits:

**Total Cholesterol (TC):** Assessed using a cholesterol levels were determined using the cholesterol oxidase method. Triglycerides (TG) were analyzed through the glycerol phosphate oxidase method. Low-Density Lipoprotein Cholesterol (LDL-C) was estimated using the Friedewald formula<sup>15</sup>, while High-Density Lipoprotein Cholesterol (HDL-C) was assessed using a direct homogeneous assay.

**Histopathological evaluation:** Prostate tissues were fixed in 10% formalin, embedded in paraffin, sectioned into 5 µm thick slices, and stained with hematoxylin and eosin (H&E) for histological analysis of the prostate tissues was performed under a light microscope to assess morphological changes, including epithelial hyperplasia, stromal hyperplasia, and inflammatory infiltration.

**Statistical analysis:** Data were presented as mean ± standard deviation (SD). One-way analysis of variance (ANOVA) was used for statistical comparisons, followed by Tukey's post-hoc test. A p-value of less than 0.05 was considered statistically significant.

## RESULTS AND DISCUSSION

The high-dose extract of *O. gratissimum* resulted in a significant ( $p < 0.05$ ) reduction in prostate weight, comparable to the effect of the standard drug, finasteride. The study results present compelling evidence regarding the potential therapeutic effects of *O. gratissimum* extract in the management of testosterone-induced benign prostatic hyperplasia (BPH) in rats, the treatment demonstrated significant therapeutic potential by alleviating prostate

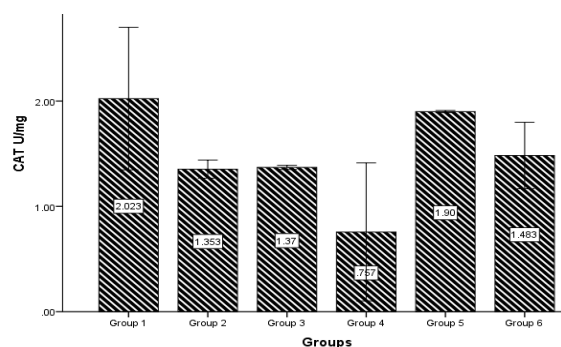
enlargement and improving biochemical markers. The extract demonstrated significant dose-dependent effects on prostate size and weight, antioxidant activity, and lipid profile, which were in alignment with the findings of previous research on the pharmacological properties of *O. gratissimum*. As shown in Table 1, the prostate weight in the normal control group was recorded at 0.85 g, which corresponds with the expected size for healthy rats. The negative control group, which was induced with BPH but did not receive any treatment, showed a significant increase in prostate size (1.45 g), demonstrating the pathological effect of testosterone-induced BPH. This is consistent with the literature, which reports that testosterone administration can lead to prostate hyperplasia and enlargement<sup>16</sup>. Treatment with *O. gratissimum* extract led to a dose-dependent reduction in prostate weight. Notably, the highest dose (600 mg/kg) showed the most significant reduction in prostate size (1.05 g), comparable to the positive control group (finasteride), which supports the potential of *O. gratissimum* as an alternative to conventional drugs like finasteride in managing BPH<sup>17</sup>. The observed reduction is likely attributed to the extract's anti-inflammatory and antioxidant properties, which are essential in suppressing tissue proliferation and alleviating inflammation in the prostate<sup>16,18</sup>.

Figure 1 and Figure 2 show the dose-dependent effects of *O. gratissimum* on catalase (CAT) and malondialdehyde (MDA) levels. The low-dose group displayed the most significant improvement in CAT activity, which indicates enhanced antioxidant defense<sup>19</sup>. Catalase is crucial for the breakdown of hydrogen peroxide, and its increased activity suggests that *O. gratissimum* may help combat oxidative stress associated with BPH<sup>20</sup>.

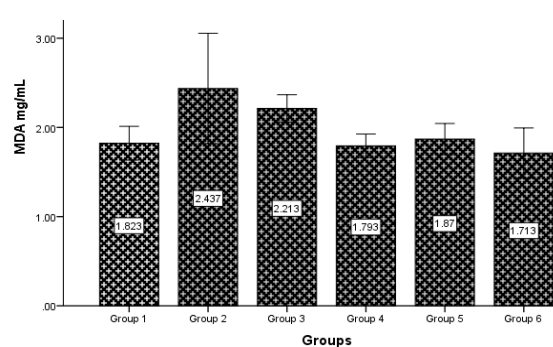
**Table 1: Effect of the *O. gratissimum* extract on prostate weight.**

S.N.	Groups	Weight (g)
1	Normal group (Feed and water only)	0.85
2	Negative control group (Induced but not treated)	1.45
3	Positive control group (Induced but not treated)	1.10
4	Induced BPH, treated with 200mg/kg of the extract	1.20
5	Induced BPH, treated with 400mg/kg of the extract	1.15
6	Induced BPH, treated with 600mg/kg of the extract	1.05

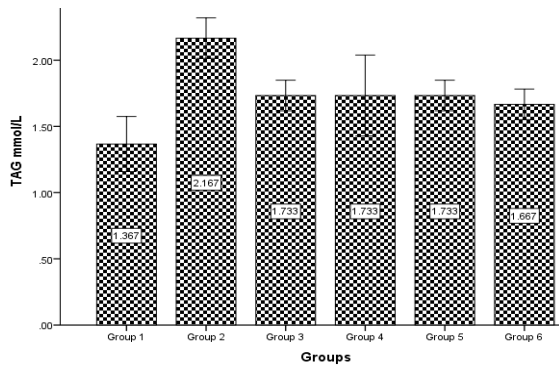
The high-dose *O. gratissimum* extract showed a significant ( $p < 0.05$ ) reduction in prostate weight, similar to the effect of standard drug (finasteride).



**Figure 1: The results showed a dose-dependent effect of *O. gratissimum* on CAT activity, with the low-dose group displaying the most significant improvement.**

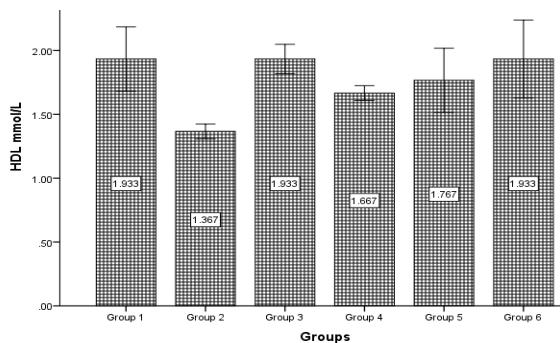


**Figure 2: The results showed a dose-dependent effect of *O. gratissimum* on MDA activity, with the high-dose group displaying the most significant improvement.**



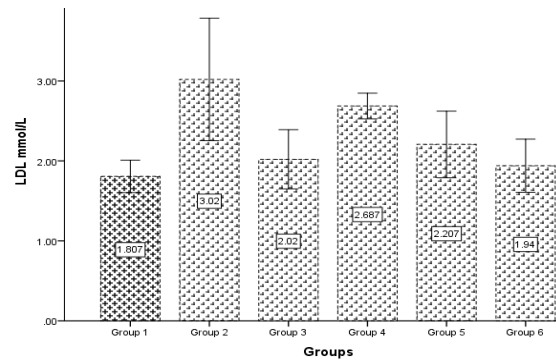
**Figure 3: Effect of Methanol extract of *O. gratissimum* on TAG level in testosterone-induced BPH rats.**

Moreover, the reduction in MDA levels in the high-dose group further supports the idea that *O. gratissimum* possesses antioxidant properties, as MDA is a marker of lipid peroxidation, a process that is elevated in oxidative stress and inflammation<sup>21</sup>. These findings align with previous studies highlighting the strong antioxidant properties of *O. gratissimum*, which have been demonstrated to mitigate oxidative damage across various tissues<sup>22</sup>.



**Figure 5: Effect of Methanol extract of *O. gratissimum* on HDL-C level in testosterone-induced BPH rats.**

The effect of *O. gratissimum* on the lipid profile is shown in Figure 3 and Figure 4. The extract significantly reduced triglycerides (TAG) and low-density lipoprotein cholesterol (LDL-C) levels were

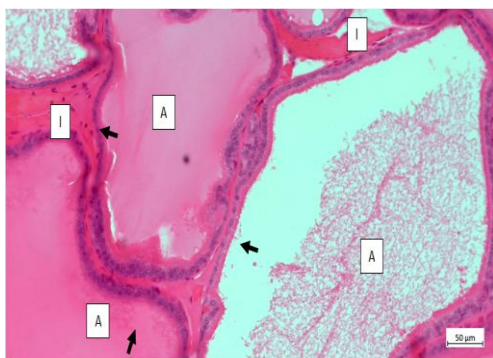


**Figure 4: Effect of methanol extract of *O. gratissimum* on LDL-C level in testosterone-induced BPH rats.**

reduced, while high-density lipoprotein cholesterol (HDL-C) levels increased. These alterations are advantageous, as elevated triglycerides (TAG) and LDL-C are known risk factors for cardiovascular disease, whereas higher HDL-C levels offer protective effects against such conditions<sup>23</sup>. The reduction in LDL-C and TAG, coupled with the increase in HDL-C, suggests that *O. gratissimum* may also have a broader systemic effect, potentially improving metabolic parameters associated with BPH. Previous research has highlighted the lipid-lowering properties of *O. gratissimum* in animal models, reinforcing the outcomes observed in this study<sup>18</sup>.

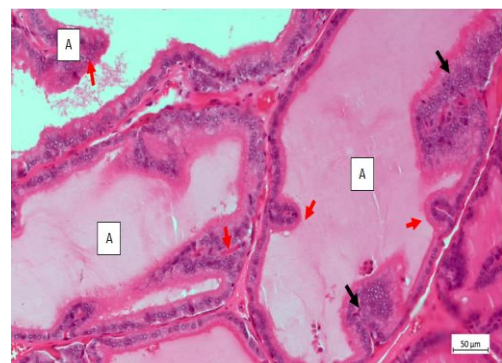
Histological examination, as seen in Plates 1–6, further corroborates the findings related to prostate enlargement and cellular morphology. In the normal group (Plate 1), the prostate showed typical histological features, including normal acini and simple cuboidal epithelial lining. In contrast, the BPH-induced rats (Plate 2) displayed epithelial hyperplasia and infoldings within the acinar lumens, indicative of prostatic hypertrophy.

These observations align with the pathological characteristics of BPH described in the literature<sup>24</sup>. Groups treated with *O. gratissimum* extract (Plates 4–6) showed milder epithelial changes, including infoldings and the presence of sloughed epithelial cells, suggesting a reduction in the severity of hyperplasia.



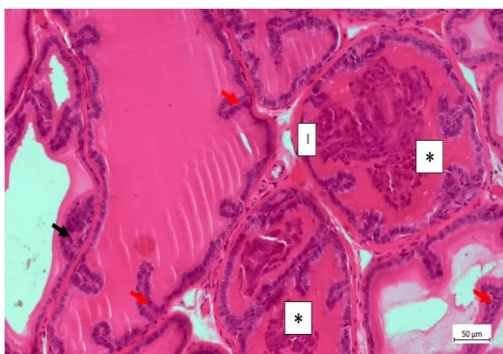
**Plate 1; Group 1: the sections of the prostate gland presented in this group showed the normal prostatic histomorphology.**

Normal acini (A), lined by simple cuboidal epithelia (arrow) were observed. The acini contained varied amounts of secretions. Prostatic interstitial (I). HE x200.



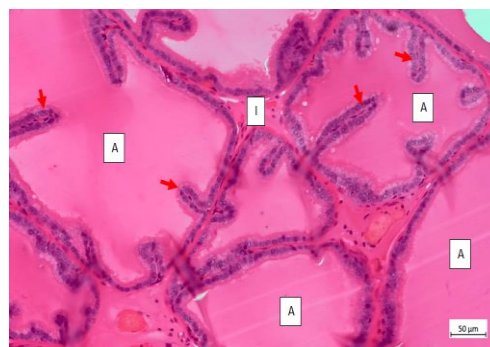
**Plate 2; Group 2: Sections of the prostate gland presented in this group showed multifocal areas of epithelial hyperplasia (black arrow) within some of the acini (A).**

Frequent epithelial infoldings (red arrow) into the acinar lumen were observed. Interstitium (I). HE x200.



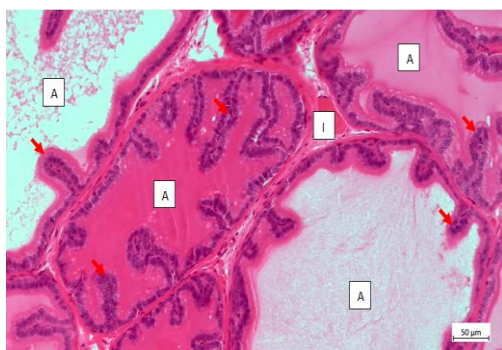
**Plate 3; Group 3:** The sections of the prostate gland presented in this group showed mild epithelial hyperplasia (black arrow) and frequent epithelial infoldings (red arrow).

Also, some the acini showed the presence of sloughed epithelia in their lumens (\*). Interstitium (I). HE x200.



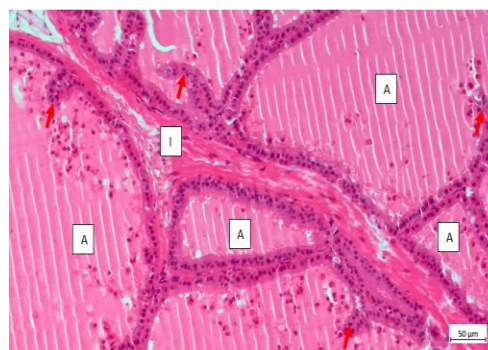
**Plate 4; Group 4:** The sections of the prostate gland presented in this group showed frequent epithelial infoldings (red arrow).

Acini (A); Interstitium (I). HE x200.



**Plate 5; Group 5:** The sections of the prostate gland presented in this group showed frequent epithelial infoldings (red arrow).

Acini (A); Interstitium (I). HE x200.



**Plate 6; Group 6:** The sections of the prostate gland presented in this group showed frequent epithelial infolding (red arrow).

In addition, there were presences of sloughed cellular debris within the lumen of the acini (A). There was also a mild-to-moderate fibrous thickening of the interstitium (I). HE x200.

The high-dose group (Plate 6) also showed mild-to-moderate fibrous thickening of the interstitium, which indicates some degree of fibrosis, a feature commonly seen in advanced BPH<sup>25</sup>. These histological changes support the conclusion that *O. gratissimum* extract can ameliorate the structural abnormalities in the prostate associated with BPH.

## CONCLUSIONS

This study provides strong evidence supporting the possible health advantages of *O. gratissimum* extract in managing testosterone-induced benign prostatic hyperplasia (BPH) in rats. The findings of this research demonstrate that *O. gratissimum* extract significantly reduces prostate size and body weight in testosterone-induced BPH rats, with the most pronounced effects seen at higher doses, which was accompanied by improvements in antioxidant activity, lipid profile, and histological features. These effects suggest that *O. gratissimum* may mitigate oxidative stress and inflammation associated with BPH while also improving metabolic health, as indicated by favourable changes in triglycerides, LDL-C, and HDL-C levels. Histological analysis further confirmed the extract's ability to reduce epithelial hyperplasia and other structural abnormalities commonly seen in BPH. These

findings are consistent with previous research emphasizing the anti-inflammatory, antioxidant, and anti-lipidemic properties of *O. gratissimum*. Given these promising outcomes, *O. gratissimum* holds potential as a natural therapeutic candidate for managing BPH and related metabolic disorders. However, further studies, including clinical trials, are necessary to comprehensively evaluate its therapeutic efficacy and determine optimal dosages for human application.

## ACKNOWLEDGEMENTS

The authors wish to acknowledge Dr. Samuel O. Onojawho for the laboratory analysis and the Department of Biochemistry for giving us the privilege to make use of Biochemistry Undergraduate laboratory.

## AUTHOR'S CONTRIBUTIONS

**Alaabo PO:** designed and supervised the study. **Achi NK:** wrote the original draft. **Ezurike PU:** reviewed and updated the manuscript. **Abuchi FJ:** conceptualization. **Nwuke CP:** literature search and data collection. **Egbonu ACC:** reviewed and co-supervised the study. **Chukwuka EW:** statistical

analysis. **Onochie AU:** results interpretation. All the authors approved the finished manuscript.

#### DATA AVAILABILITY

Findings will be made available upon reasonable request from the corresponding author.

#### CONFLICTS OF INTERESTS

None to declare.

#### REFERENCES

- Achi NK, Eleazu CO, Onyeabo C, Kalu W, Eleazu K. *Syzygium malaccense* leaves methanol extract modulate some biochemical and inflammatory markers and prostate histology of testosterone-estradiol valerate induced benign prostatic hyperplasia in rats. *Avicenna J Phytomed* 2024; 14 (3): 305-324. <https://doi.org/10.22038/AJP.2023.23526>
- Montioni R, Scarpelli M, Mazzucchelli R, Cheng L. Benign prostatic hyperplasia: The pathological features and current understanding. *J Urol* 2018; 199(2): 521-531.
- McVary KT. The management of benign prostatic hyperplasia: The role of  $\alpha$ -blockers and 5 $\alpha$ -reductase inhibitors. *American J Clin Urol* 2016; 23(4): 1-11.
- Shah SA, Khan R, Ali S. Mechanisms underlying benign prostatic hyperplasia. *Prostate cancer and prostatic diseases* 2017; 20(3): 276-283.
- Haider S, Alhaddad A, Bashir H. Dihydrotestosterone in benign prostatic hyperplasia: A review of the molecular mechanisms. *Endocrinol Rev* 2015; 36(2): 123-134.
- Kachroo D, Gupta S, Bhattacharya S. Oxidative stress and inflammation in benign prostatic hyperplasia. *Biol Chem* 2020; 405(5): 495-505.
- Berges R, Jensen R, Anderson S. Adverse effects of BPH treatment and the search for safer alternatives. *J Clin Med* 2019; 8(7): 1150.
- Akinmoladun A, Oyebo O, Bamidele O. Pharmacological properties of *Ocimum gratissimum* in oxidative stress management. *J Med Plants* 2019; 16(3): 74-82.
- Chaudhary N, Gupta R, Soni R. Herbal interventions in benign prostatic hyperplasia: A review. *J Nat Med* 2018; 72(2): 123-135.
- Adeyemi O, Olorunsogo O, Adebayo T. Antioxidant properties of *Ocimum gratissimum* in mitigating oxidative stress. *African J Pharm Sci* 2020; 14(4): 240-248.
- Sinha AK. Colorimetric assay of catalase activity. *Analyt Biochem* 1972; 47(2): 389-394.
- Kogan S, Muntean D, Novak I. Induction of BPH in rats using testosterone propionate: A reproducible animal model. *J Pharmacol Methods* 2014; 45(7): 741-745.
- Ohkawa H, Ohishi N, Yagi K. Assay for lipid peroxides in animal tissues by thiobarbituric acid reaction. *Analyt Biochem* 1979; 95(2): 351-358. [https://doi.org/10.1016/0003-2697\(79\)90738-3](https://doi.org/10.1016/0003-2697(79)90738-3)
- Aebi H. Catalase *in vitro*. *Methods in Enzymology* 1984; 105: 121-126
- Friedewald W, Levy R, Fredrickson D. Estimation of the concentration of low-density lipoprotein cholesterol in plasma, without use of the preparative ultracentrifuge. *Clin Chem* 1972; 18(6): 499-502. PMID: 4337382
- Zhao W, Zhang X, Wang H. Testosterone-induced prostatic hyperplasia and the potential of herbal treatments. *Phytomed* 2019; 64: 132-140.
- Yuan Y, Zhang W. The efficacy of finasteride in treating benign prostatic hyperplasia. *J Urol* 2020; 47(3): 59-67.
- Hussain A, Akhtar M, Khan F. Anti-inflammatory effects of *Ocimum gratissimum* in prostatic diseases. *Pharmacol Rep* 2019; 71(5): 888-895.
- Akinmoladun A, Oyebo O, Akinmoladun I. Antioxidant activity of *Ocimum gratissimum* in prostate tissues. *Phyto Res* 2020; 34(6): 1004-1012.
- Wang Z, Liu W, Liu D. Catalase and its role in oxidative stress during benign prostatic hyperplasia. *Antioxidant Therapy* 2021; 10(3): 119-130.
- Thomson M, Cooper A, Patel P. Reduction of oxidative stress in benign prostatic hyperplasia: Effects of antioxidant therapy. *J Cell Biochem* 2022; 123(1): 32-45.
- Fokunang C, Akinmoladun A, Yaro H. The antioxidant properties of *Ocimum gratissimum* in mitigating tissue damage in various organs. *Free Rad Res* 2018; 52(9): 869-877.
- Gómez-Sánchez C, Villalobos A, Ortega P. The role of lipid metabolism in prostate diseases: A focus on benign prostatic hyperplasia. *Lipids Health Dis* 2021; 20(1): 12-20.
- Reagan S, Morrison J. Histological changes in benign prostatic hyperplasia: Insights from animal models. *J Pathol* 2020; 58(5): 110-118.
- Böhm M, Ziegler W. Histopathological features of benign prostatic hyperplasia and their implications in advanced disease management. *J Urol* 2020; 204(2): 191-199.