



## RESEARCH ARTICLE

## IMPACT OF 3D PRINTING IN RECONSTRUCTION OF MAXILLOFACIAL BONE DEFECTS EXPERIMENTAL STUDY IN A MILITARY HOSPITAL IN SANA'A CITY, YEMEN

Lutf Mohammed Al-Rahbi<sup>1,2</sup>, Hamzah Hussein Mohammed Setten<sup>2</sup>,  
 Hassan Abdulwahab Al-Shamahy<sup>3,4</sup>

<sup>1</sup>Department of Oral and Maxillo-Facial Surgery, Faculty of Dentistry, Sana'a University, Republic of Yemen.

<sup>2</sup>Yemen Medical Specialist Council, Ministry of Health and population, Yemen.

<sup>3</sup>Departement of Basic Sciences, Faculty of Dentistry, Sana'a University, Republic of Yemen.

<sup>4</sup>Medical Microbiology and Clinical Immunology Department, Faculty of Medicine and Health Sciences, Sana'a University.

### Article Info:



#### Article History:

Received: 13 December 2024

Reviewed: 11 January 2025

Accepted: 22 February 2025

Published: 15 March 2025

#### Cite this article:

Al-Rahbi LM, Setten HHM, Al-Shamahy HA. Impact of 3D printing in reconstruction of maxillofacial bone defects experimental study in a military hospital in Sana'a city, Yemen. *Universal Journal of Pharmaceutical Research* 2025; 10(1): 31-38.  
<http://doi.org/10.22270/ujpr.v10i1.1271>

#### \*Address for Correspondence:

Dr. Hassan A. Al-Shamahy, Departement of Basic Sciences, Faculty of Dentistry, Sana'a University, Republic of Yemen. Medical Microbiology and Clinical Immunology Department, Faculty of Medicine and Health Sciences, Sana'a University. Tel: +967-1-239551;  
 E-mail: [shmahe@yemen.net.ye](mailto:shmahe@yemen.net.ye)

### Abstract

**Background and aims:** The study explores the use of PEEK and PMMA as alternatives for 3D reconstruction of orbital bone defects. It aims to evaluate their durability, develop a standardized protocol, and design implant-specific implants using 3D printing technology.

**Subjects and methods:** A study at the Military Hospital in Sana'a, Yemen, found maxillofacial fractures in six patients who underwent maxillofacial reconstruction using 3D printing technology. The patients had previously undergone unsuccessful traditional treatments. The study involved preoperative assessments, CT scans, and functional evaluations. Custom 3D printed implants were designed using GOM and ATOS, and surgical procedures were performed under general anesthesia.

**Results:** A group of patients aged 20-43 years, with a mean age of 28.8 years, experienced pain, aesthetic deformity, limited mouth opening, difficulty eating, and bacterial infections. Causes included G.S.I., RTA, bomb explosion, and falls from height. The study found that all patients had unilateral fractures, with 33.3% having segmental fractures, 66.7% having displacement, and 50 having tripod fractures. Debridement operation was performed in all patients, with bone grafting and ORIF performed in 83.3%. Instability, insufficient, and infection were the most common reasons for failure.

**Conclusion:** This study highlights the potential of 3D printing technology in enhancing the outcomes of maxillofacial bone defect reconstruction by use PEEK and PMMA materials, especially in patients with prior treatment failures.

**Keywords:** Bioceramics, maxillofacial bone defect, reconstructive surgical procedures, three-dimensional (3D) printing technology, PEEK, PMMA.

### INTRODUCTION

Decreased quality of life can be the result of critical functional and aesthetic problems caused by bone deformities in the maxillofacial region<sup>1</sup>. Infection, trauma, congenital conditions, or neoplastic surgery, can all be the cause of these deformities<sup>1,2</sup>. Reconstructive operation, which can be challenging for both surgeons and patients, is necessary to restore the functional and aesthetic roles of complex anatomical areas<sup>1</sup>. Polyether ether ketone (PEEK), autologous bone grafting, or titanium, have been used to coat bone defects in cases prior to acknowledged in the researches<sup>3</sup>. Nevertheless, each material presents some limits elevating the requirement for additional research to establish the superlative request for bone

reconstruction in the maxillofacial locality. Biocompatibility, non-allergenic activities, radiopacity, affordability, ease of use, and satisfactory strength are all general prerequisites for an ideal implant<sup>1,4,5</sup>. Furthermore, implants with critical biological properties such as osteoconduction and osteoinduction to improve implant ingrowth and dimensional strength make them more useful for bone restoration<sup>1,6,7</sup>. The ability to passively host osteogenic cells, including osteocytes, and direct their migration into the graft to promote its ingrowth is known as osteoconduction<sup>2,8</sup>. To allow migration within a 3D structure, a microporous structure is required<sup>9</sup>.

It is hard to duplicate the dynamic properties of native bone with those of standard implants. Growth factors, proper vascularity, and stability for osteoblasts,

osteoclasts, and osteocytes all depend on a mineral matrix. Because autologous bone grafting contains osteoconductive, osteoinductive, and osteogenic qualities, it has the best biocompatibility and is consequently regarded as the gold standard<sup>2,6,8,11</sup>. Significant disadvantages include acceptor site resorption, donor site morbidity, restricted supply of appropriate donor bone, and extended surgical duration<sup>6,10,11</sup>. Because of its strength, osseointegration ability, and biocompatibility, titanium is a widely used material<sup>5,12</sup>. However, compared to bone grafts and bioceramics, it has a greater infection rate, produces radiological artifacts, and causes thermal discomfort<sup>9,13,14</sup>. PEEK implants have weak osteoconductive qualities, low bioactivity, and good strength<sup>9,12,15</sup>. Bioceramic patient-specific implants (PSIs) have attracted attention recently as a valuable alternative to traditional materials for the reconstruction of bone defects in the craniomaxillofacial region<sup>6,12,16</sup>. Three-dimensional (3D) printing technology has the probable to combine the biomechanical possessions of bioceramics in a PSI<sup>12,17,18</sup>, a relatively new technique that is regarded as the future of transplant medicine<sup>19</sup>. Bioceramic PSIs can be printed using computer-aided design and manufacturing (CAD/CAM) to create a biocompatible scaffold that guides osteoblasts to replace bone defects in the craniomaxillofacial region without donor site morbidity<sup>20</sup>. The implant stimulates osteogenesis and fibrovascular ingrowth<sup>18,21</sup>.

The most common form is hydroxyapatite (HA), which is occasionally mixed with growth hormones such bone morphogenic protein 2 (BMP2)<sup>22,23</sup>. Since an osteoinductive factor, BMP2 promotes angiogenesis and osteoblast development. A mix of osteoconductive carriers, such as HA scaffolds or autologous and allogeneous bone transplants, are required for its application<sup>2</sup>. The therapeutic application of HA bioceramic PSIs in the craniomaxillofacial region is not well documented in research<sup>9,16,17</sup>. Furthermore, opinions about the ideal ratio of osseointegration to strength are divided<sup>16,20</sup>. The primary difference in mechanical qualities is the pore design, which is required to improve bone ingrowth in the implant<sup>24</sup>. For instance, the conventional pore arrangement is not as robust as the triangular periodic minimum surface (TPMS) approach<sup>20,25</sup>. The PSIs created for clinical cases in this study used TPMS<sup>22,23</sup>. The aim of the study was to assess the biocompatibility and biomechanical behaviour of HA bioceramic PSIs in relation to autologous bone implants, titanium, and PEEK. To illustrate the clinical results of these implants in reconstructive surgery for maxillofacial bone deformities, six clinical examples were included.

## SUBJECTS AND METHODS

**Study Design:** A serial clinical follow-up study.

**Study population:** All patients attending the Military hospital between the first of January 2024 and the end of December 2024 (Time allowed for clinical work for the board's degree).

**Data collection procedure:** All patients who met the predetermined inclusion criteria were immediately admitted to the OMFD inside the Yemeni military hospital. There, they were given a detailed explanation of the study protocol and their written informed consent was duly obtained. A form created especially for this purpose is used to meticulously record pertinent demographic data, such as age, medical history, behavioral patterns, and contact information. The diagnosis process began with a thorough review of the patients' medical history, a careful clinical examination, and a thorough radiological evaluation, which included obtaining a standard CT scan with 3D reconstruction, including axial and coronal views, as a preoperative procedure. Furthermore, laboratory tests were carefully performed on each patient that was part of the study. Using 3D printing technology, these six patients underwent maxillofacial repair as part of their treatment. Six patients with maxillofacial bone abnormalities who had previously received ineffective conventional therapies were enrolled in this exploratory trial. All participants provided informed consent. Preoperative assessments involved medical history reviews, imaging studies (CT scans), and functional evaluations. Custom 3D printed implants were designed using GOM; ATOS, Braunschweig, Germany based on high-resolution CT scans to create accurate models of the defects. The implants were fabricated using 3D printing technology (FDM, SLA) with biocompatible materials such as PMMA in five cases, and PEEK in one case as material for craniofacial augmentation and reconstruction. Surgical procedures were performed under general anesthesia, where the failed grafts were removed and the 3D printed implants were placed and fixed using screws and plates. Postoperative care included monitoring for complications and follow-up assessments at 1, 2, 8, 12, 16 weeks.

**Statistical Analysis:** Data analyzed by using statistical software SPSS version 20 (SPSS Inc., Chicago, IL, USA). Descriptive analyses: proportions, percentages, and frequency distribution were performed.

## RESULTS

Table 1 shows gender and age distribution of six patients who underwent maxillofacial reconstruction using 3D printing technology, a case series at the Military Hospital in Sana'a City. There are 100% males and 0.0% females, the mean age of the group was 28.8 years  $\pm$  9.3 years and the ages of patients ranged from 20 to 43 years. Table 2 shows the complaints of patients who underwent maxillofacial reconstruction using 3D printing technology before the operation. Total 50% of patients had pain, 100% had aesthetic deformity, 33.3% had limited mouth opening, 16.7% had difficulty eating and 16.7% had bacterial infection. Table 3 shows the etiology of maxillofacial fractures in patients who underwent maxillofacial reconstruction using 3D printing technology. In 33.3% the cause was G.S.I, 16.7% direct impact (RTA), 50% bomb explosion and none due to falls from height (0.0%). Table 4 shows the locations of facial and

maxillofacial fractures in patients who underwent maxillofacial reconstruction using 3D printing technology.

**Table 1: Gender and age distribution of six patients who underwent maxillofacial reconstruction using 3D printing technology, a case series at the Military Hospital in Sana'a city.**

Characters	N (%)
Sex	
Male	6 (100)
Female	0 (0.0)
Age in Years	
Twenties	3 (50)
Thirties	2 (33.3)
Forties	1 (16.7)
Mean	28.8 years
SD	9.3 years
Median	27.5 years
Mode	20 years
Min to Max	20 - 43 years

**Table 2: Complaints of patients who underwent maxillofacial reconstruction using 3D printing technology before the operation.**

Complains	N (%)
Pain	3 (50)
Aesthetics deformity	6 (100)
Limited mouth open	2 (33.3)
Difficulty to eat	1 (16.7)
Infection	1 (16.7)
Total	6 (100)

**Table 3: Etiology of maxillofacial fractures in patients who underwent maxillofacial reconstruction using 3D printing technology.**

Etiology	N (%)
G.S.I	2 (33.3)
RTA	1 (16.7)
Bomb explosion	3 (50)
Fall from height	0 (0.0)
Total	6 (100)

**Table 4: Locations of maxillofacial fractures in patients who underwent maxillofacial reconstruction using 3D printing technology.**

Sites	N (%)
Mandible	1 (16.7)
Maxilla	3 (50)
Nasal	1 (16.7)
Zygoma	4 (66.7)
Orbit	5 (83.3)
Frontal	2 (33.3)
Total	6 (100)

The fracture occurred in the mandible in 16.7%, in the maxilla in 50%, in the nose in 16.7%, in the cheekbone (zygoma) in 66.7%, in the orbit in 83.3%, and in the frontal in 33.3%. Table 5 shows the types of maxillofacial fractures in patients who underwent maxillofacial reconstruction using 3D printing technology. Comminuted fracture occurred in 83.3% of patients, and 16.7% had simple fracture and maxillary sinus fracture. There were no cases of compound or complex fractures. Table 6 shows the orientation of jaw and facial fractures in patients who underwent jaw and

facial reconstruction using 3D printing technology. Unilateral fractures were recorded in all patients (100%), 33.3% had segmental fractures, 66.7% had displacement, and 50 had tripod fractures. Table 7 shows the types of previous operations and reasons for failure of the first operation for maxillofacial fracture patients who underwent maxillofacial reconstruction using 3D printing technology. Debridement operation (devitalization) was performed in all patients (100%), bone grafting was performed in 33.3% and open mandibular fixation (ORIF) was performed in 83.3%. Considering the reasons for previous failure, instability occurred in 33.3%, insufficient in 100% and infection in 33.3%.

**Table 5: Types of maxillofacial fractures in patients who underwent maxillofacial reconstruction using 3D printing technology.**

Types	N (%)
Comminuted	5 (83.3)
Compound	0 (0.0)
Complex	0 (0.0)
Simple	1 (16.7)
Involved maxillary sinus	0 (0.0)
Total	6 (100)

**Table 6: Distant of maxillofacial fractures in patients who underwent maxillofacial reconstruction using 3D printing technology.**

Distant	N (%)
Bilateral	0 (0.0)
Unilateral	6 (100)
Segmental	2 (33.3)
Displaced	4 (66.7)
Tripod	3 (50)
Total	6 (100)

**Table 7: Types of past operation and causes of failure in the previous operation for maxillofacial fractures patients who underwent maxillofacial reconstruction using 3D printing technology.**

Characters	N (%)
<b>Types of operation</b>	
Debridement	6 (100)
Bone graft	2 (33.3)
ORIF	5 (83.3)
Observation	0 (0.0)
<b>Causes of failure</b>	
Instability	3 (50)
Not enough	6 (100)
Infection	2 (33.3)
Other causes	1 (16.7)
Total	6 (100)

Table 8 shows the impact of injuries on the ocular tissues among maxillofacial fracture patients who underwent maxillofacial reconstruction using 3D printing technology. The papyrus plate was affected in 50% of patients, the orbital rim in 66.7%, the lateral wall in 83.3%, the floor in 66.7% and the roof in 16.7%. At 16-weeks follow-up, there were no wound opening, facial asymmetry, infection, instability, facial nerve injury, and antibiotic use, and only one case of scarring was recorded.

**Table 8: Effect of the injuries on eye tissues among maxillofacial fractures patients who underwent maxillofacial reconstruction using 3D printing technology.**

Characters	N (%)
Lamina papyreacea	3 (50)
Orbital rim	4 (66.7)
Lateral wall	5 (83.3)
Medial wall Floor	0 (0.0)
Floor	4 (66.7)
Roof	1 (16.7)
Isolated orbital	0 (0.0)
Total	6 (100)

Table 9 shows the postoperative follow-up among maxillofacial fracture patients who underwent maxillofacial reconstruction using 3D printing technology. Considering the follow-up after 1 week of operation, wound opening occurred in 16.7%, facial asymmetry occurred in 16.7%, infection occurred in 16.7%, instability occurred in 16.7%, scar formation occurred in 33.3%, and continuous antibiotic use occurred in all patients (100%). At 2-weeks follow-up, there was 16.7% wound opening, no facial asymmetry (0.0%), 16.7% infection, 16.7% instability, ....., 33.3% scarring, and 33.3% continuous antibiotic use.

**Table 9: The follow up after surgery among maxillofacial fractures patients who underwent maxillofacial reconstruction using 3D printing technology.**

Characters	Follow up after				
	1 week	2 weeks	8 weeks	12 weeks	16 weeks
Wound dehiscence	1 (16.7)	1 (16.7)	0 (0.0)	0 (0.0)	0 (0.0)
Facial asymmetry	1 (16.7)	0 (0.0)	0 (0.0)	0 (0.0)	0 (0.0)
Allergy	0 (0.0)	0 (0.0)	0 (0.0)	0 (0.0)	0 (0.0)
Infections	1 (16.7)	0 (0.0)	0 (0.0)	0 (0.0)	0 (0.0)
Instability	1 (16.7)	1 (16.7)	1 (16.7)	0 (0.0)	0 (0.0)
Scar	2 (33.3)	2 (33.3)	1 (16.7)	1 (16.7)	1 (16.7)
Antibiotics	6 (100)	2 (33.3)	0 (0.0)	0 (0.0)	0 (0.0)

Table 10 shows the postoperative evaluation and recovery experience among maxillofacial fracture patients who underwent maxillofacial reconstruction using 3D printing technology.

**Table 10: Post operative assessment and recovery experience among maxillofacial fractures patients who underwent maxillofacial reconstruction using 3D printing technology.**

Characters	N (%)
Satisfied for results	
Very satisfied	4 (66.6)
satisfied	1 (16.7)
Natural	1 (16.7)
dissatisfied	0 (0.0)
Total	6 (100)

**Table 11: Post operative assessment and quality of life among maxillofacial fractures patients who underwent maxillofacial reconstruction using 3D printing technology.**

Characters	N (%)
Eating well	5 (83.3)
Speaking well	5 (83.3)
Social interaction	6 (100)
Emotional well being	6 (100)
Satisfied quality of life	5 (83.3)
Total	6 (100)

The physicians and patients were very satisfied with the results in 66.6% of cases, 16.7% had a satisfied result, 16.7% had a normal result and no cases of dissatisfaction with the results occurred. Table 11 shows the postoperative assessment and quality of life among maxillofacial fracture patients who underwent maxillofacial reconstruction using 3D printing technology. 83.3% of patients reported the ability to eat

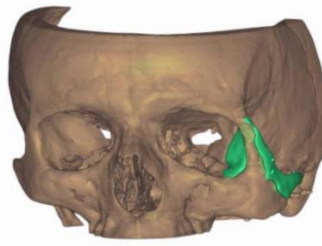
well, speak well in 83.3%, social interaction in 100%, emotional well-being in 100% of cases, and the quality of life of patients was excellent in 83.3% of patients. The drawings in Figure 1 to Figure 9 show the planning, surgery and designs for 3 cases from our patients included in the study. In case 1: showing the patient's preoperative clinical situation at 45 degrees left. Then the postoperative clinical situation is shown at 45 degrees left, noting the positive change after the operation.

## DISCUSSION

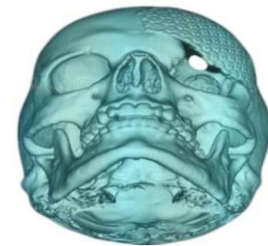
In the current study, 50% of patients experienced pain, 100% experienced cosmetic deformity, 33.3% experienced limited mouth opening, 16.7% experienced difficulty eating, and 16.7% experienced bacterial infection. The following findings are similar to those previously reported: facial bone fractures, like other fractures, may be associated with pain, bruising, and swelling of the surrounding tissues (these symptoms can also occur in the absence of fractures); severe nosebleeds may be associated with nose, skull base, or maxilla fractures; nasal fractures may be associated with nasal deformity, along with swelling and bruising<sup>27</sup>; facial deformity, such as sunken cheekbones or misaligned teeth, suggests fractures; asymmetry may also indicate facial fractures or nerve damage<sup>28</sup>; and those who have a mandibular fracture frequently experience pain and difficulty opening their mouths, as well as numbness of the lip and chin<sup>29</sup>. Also with Le Fort fractures, the midface may move relative to the rest of the face or skull<sup>30</sup>. In the current study when considering the causes of injuries. 33.3% were caused by gunshot, 16.7% by Road Traffic Accident (RTA), 50% by bomb blast and none by falling from a height (0.0%).



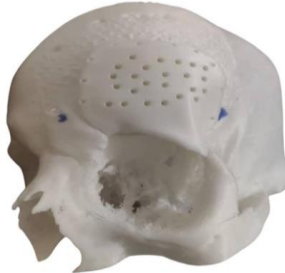**Figure 1: Digital design of the PSI 3D model.**



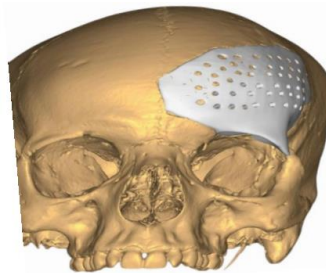
**Figure 2: Digital design of the design model.**



**Figure 3: Digital design of reconstruction by traditional method.**



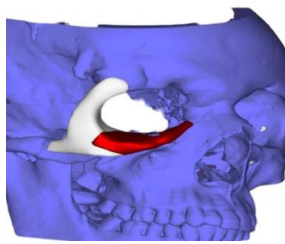
**Figure 4: Digital design of model reconstitute by 3D method.**



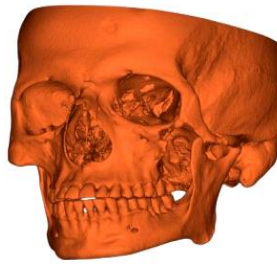**Figure 5: Digital design model.**



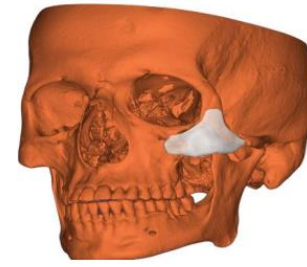
**Figure 6: Digital design of 3D implant.**



**Figure 7: Digital design model for case no. 3.**



**Figure 8: Digital design of the PSI 3D model.**



**Figure 9: Digital design of the design model.**

These findings differ from those reported elsewhere in the world where mechanisms of injury such as falls, assaults, sports injuries and motor vehicle accidents are common causes of facial trauma in children<sup>29,31</sup> as well as adults<sup>32</sup>. Facial injuries is also frequently caused by indirect assaults and hits from fists or objects<sup>26,33</sup>. The primary cause of facial trauma in our study was war-related injuries including gunfire and explosions. Other reasons include animal attacks and occupational injuries like industrial accidents<sup>34</sup>. One of the main causes of facial injuries is motor vehicle trauma, which typically happens when the face strikes an interior component of the car, such the steering wheel<sup>35</sup>. Furthermore, when airbags are deployed, they may result in facial lacerations and corneal abrasions<sup>35</sup>. In the current study, fractures occurred in the mandible (16.7%), the maxilla (50%), the nose (16.7%), the cheekbone (66.7%), the orbit (83.3%), and the frontal (33.3%). Also the papyrus plate was affected in 50% of patients, the orbital rim in 66.7%, the lateral wall in 83.3%, the floor in 66.7% and the roof in 16.7%. These findings are similar to those reported previously, in which the most commonly affected facial bones include the nasal bone (nose), the maxilla, and the mandible. The mandible may fracture at the ossicle, body, angle, ramus, and condyle<sup>29</sup>. Other fracture locations include the frontal bone (forehead) and the

zygoma (cheekbone)<sup>36</sup>. The palate's bones and those that unite to form the orbit can also sustain fractures. This prospective study aimed to use 3D printing to reconstruct maxillofacial bone defects resulting from various injuries and to evaluate the associated complications, evaluation experience, recovery and quality of life after surgery using materials PEEK and PMMA with the aim of avoiding bone grafting and reducing surgical time, an idea similar to the use of HA bioceramic blocks and particles already used in maxillofacial surgery in the 1980s<sup>37,38</sup>. However, it was difficult to prevent these particles from migrating<sup>37</sup>. Currently, these bioceramic materials can be used to fabricate PSIs<sup>18</sup>. HA bioceramic PSIs provide a volumetrically stable scaffold of biocompatible material for the reconstruction of maxillofacial bone defects<sup>18</sup>. PSIs, regardless of the material used, are superior to standard implants in terms of fit accuracy, reduced surgical time and risk of infection, stability and implant-bone contact<sup>4,39,40</sup>. In particular, when using surgical navigation, accuracy is enhanced<sup>40</sup>. The results of our study have confirmed previous facts. In the present study, patients who underwent maxillofacial reconstruction using 3D printing technology were preoperatively treated using classical surgical methods. Preoperatively, 50% of patients experienced pain, 100% experienced aesthetic

deformity, 33.3% experienced limited mouth opening, 16.7% experienced difficulty in eating and 16.7% experienced bacterial infection, but these problems disappeared after they underwent maxillofacial reconstruction using 3D printing technology using PEEK and PMMA implants. Bioceramic fillings are biomimetic and eliminate the need for bone grafting<sup>17</sup>. They are osteoconductive, and the large pores in the gyroids have the ability to direct bone cells and facilitate osteogenesis and fibrovascular growth *in vitro*<sup>18</sup>. *In vivo*, osseointegration could not be objectively assessed on CT images 16 weeks after surgery in the six cases. However, in the clinical cases performed by Verbist, *et al.*<sup>40</sup>, a perfect osseous contact and signs of bone formation were observed between the bioceramic fillings and the bone<sup>41,42,43</sup>. This indicates beneficial healing, fibrovascularization and mineralization around the implant. Bioceramic fillings have proven to be beneficial due to their use as an internal filling rather than an external filling. This has led to an excellent aesthetic result in this important anatomical area. In order to be able to observe clear signs of osseointegration radiographically, a longer follow-up period of up to twelve months is required<sup>9,16</sup>. In the current study the post operative assessment and recovery experience among maxillofacial fractures patients who underwent maxillofacial reconstruction using 3D printing technology results showed that physicians and patients were very satisfied with the results in 66.6% of cases, 16.7% had a satisfied result, 16.7% had a normal result and no cases of dissatisfaction with the results occurred. These results are similar to that reported by researchers when they compare the maxillofacial reconstruction using 3D printing technology with classical surgery and bone grafts as their conclusions stated that “3D printed bioceramic implants have great potential in maxillofacial reconstruction surgery”. According to studies, these novel implants have a number of advantages over traditional methods in terms of biocompatibility and biomechanical behavior, and a wide range of applications are feasible. To assess the osseointegration progress radiographically, a longer follow-up period is required. However, we advise using them in load-sharing anatomical systems for reconstruction or aesthetic reasons because of their superior osseointegration ability and biocompatibility. To assess the long-term impacts of this promising biomaterial, more investigation is required<sup>41-44</sup>.

#### Limitations of the study

A limitation of the study is that the research was conducted to analyze a small, specific group of materials used in bone reconstruction in maxillofacial surgery. Both materials utilized are radiolucent materials, which poses challenges in monitoring and assessment. Additionally, polymethyl methacrylate (PMMA) requires sufficient thickness; insufficient thickness compromises its strength and increases the risk of fracturing when secured with screws. As pioneers in implementing this type of prosthetic in Yemen, we encountered difficulties related to the designer's capacity to achieve optimal alignment of soft tissues and appropriate thickness. This necessitated in-

operation adjustments for several cases; This opens the door to the possibility of selection and publication bias. However, our search was conducted from a rigorous critical perspective, prioritizing the inclusion of the most relevant articles on this topic. Also one of the main limitations of this study was not including long-term follow-up.

#### CONCLUSION

This study highlights the potential of 3D printing technology in enhancing the outcomes of maxillofacial bone defect reconstruction by PEEK and PMMA materials, especially in patients with prior treatment failures.

#### ACKNOWLEDGEMENT

Authors are thankful for the Sana'a University, Republic of Yemen to provide necessary facilities during the study.

#### AUTHOR'S CONTRIBUTIONS

**Setten HHM:** Formal analysis, conceptualization, data organization, and clinical and laboratory examinations to obtain a board's degree in Oral and Maxillofacial Surgery. **Al-Rahbi LM:** critical review, supervision. **Al-Shamahy HA:** statistical analysis, supervision. Final manuscript was checked and approved by all authors.

#### DATA AVAILABILITY

The accompanying author can provide the empirical data that were utilized to support the study's conclusions upon request.

#### CONFLICT OF INTEREST

None to declare.

#### REFERENCES

1. Ghantous Y, Nashef A, Mohanna A, Abu-El-Naaj I. Three-dimensional technology applications in maxillofacial reconstructive surgery: Current surgical implications. *Nanomaterials (Basel)* 2020 Dec 16; 10(12):2523. <https://doi.org/10.3390/nano10122523>
2. Wang W, Yeung KW. Bone grafts and biomaterials substitutes for bone defect repair: A review. *Bioact Mater* 2017; 2: 224–247. <https://doi.org/10.1016/j.bioactmat.2017.05.007>
3. Alasseri N, Alasraj A. Patient-specific implants for maxillofacial defects: Challenges and solutions. *Maxillofac Plast Reconstr Surg* 2020; 42: 1–8. <https://doi.org/10.1186/s40902-020-00262-7>
4. Kanno T, Sukegawa S, Karino M, Furuki Y. Navigation-assisted orbital trauma reconstruction using a bioactive osteoconductive/bioresorbable u-HA/PLLA System. *J Maxillofac Oral Surg* 2019; 18: 329–338. <https://doi.org/10.1007/s12663-019-01207-y>
5. Cleemput S, Huys SE, Cleymaet R, Cools W, Mommaerts MY. Additively manufactured titanium scaffolds and osteointegration—Meta-analyses and moderator-analyses

- of *in vivo* biomechanical testing. *Biomater Res* 2021; 25: 1–17.
6. Doi K, Kubo T, Makihara Y, *et al.* Osseointegration aspects of placed implant in bone reconstruction with newly developed block-type interconnected porous calcium hydroxyapatite. *J Appl Oral Sci* 2016; 24: 325–331. <https://doi.org/10.1590/1678-775720150597>
  7. Chen J, Xiao J, Han X, Sima X, Guo W. An HA/PEEK scaffold with modified crystallinity via 3D-bioprinting for multiple applications in hard tissue engineering. *Biomater* 2023; 18: 065021. <https://doi.org/10.1088/1748-605X/ad0476>
  8. Fillingham Y, Jacobs J. Bone grafts and their substitutes. *Bone Jt. J* 2016; 98B: 6–9. <https://doi.org/10.1302/0301-620X.98B.36350>
  9. Systemans S, Cobraiville E, Camby S, *et al.* An innovative 3D hydroxyapatite patient-specific implant for maxillofacial bone reconstruction: A case series of 13 patients. *J Cranio-Maxillofac Surg* 2024; 52: 420–431. <https://doi.org/10.1016/j.jcms.2024.02.026>
  10. Bedogni A, Bettini G, Bedogni G, *et al.* Safety of boneless reconstruction of the mandible with a CAD/CAM designed titanium device: The Replica Cohort Study. *Oral Oncol* 2021, 112, 105073. <https://doi.org/10.1016/j.oraloncology.2020.105073>
  11. Järvinen S, Suojanen J, Kormi E, *et al.* The use of patient specific polyetheretherketone implants for reconstruction of maxillofacial deformities. *J Cranio-Maxillofac Surg* 2019; 47: 1072–1076. <https://doi.org/10.1016/j.jcms.2019.03.018>
  12. Kauke-Navarro M, Knoedler L, Knoedler S, *et al.* Balancing beauty and science: A review of facial implant materials in craniofacial surgery. *Front Surg* 2024; 11: 1348140. <https://doi.org/10.3389/fsurg.2024.1348140>
  13. Ferraz MP. Bone grafts in dental medicine: An overview of autografts, allografts and synthetic materials. *Materials* 2023; 16: 4117. <https://doi.org/10.3390/ma16114117>
  14. Bohner L, Dirksen D, Hanisch M, Sesma N, Kleinheinz J, Meier N. Artifacts in magnetic resonance imaging of the head and neck: Unwanted effects caused by implant-supported restorations fabricated with different alloys. *J Prosthet Dent* 2023; in press. <https://doi.org/10.1016/j.prosdent.2023.08.018>
  15. Saponaro G, Todaro M, Barbera G, *et al.* Patient-specific facial implants in polyetheretherketone and their stability: A preliminary study. *Ann Plast Surg* 2023; 90: 564–567. <https://doi.org/10.1097/SAP.0000000000003527>
  16. Brie J, Chartier T, Chaput C, *et al.* A new custom made bioceramic implant for the repair of large and complex craniofacial bone defects. *J Cranio-Maxillofac Surg* 2013; 41: 403–407. <https://doi.org/10.1016/j.jcms.2012.11.005>
  17. Staffa G, Barbanera A, Faiola A, *et al.* Custom made bioceramic implants in complex and large cranial reconstruction: A two-year follow-up. *J Cranio-Maxillofac Surg* 2012; 40: e65–e70. <https://doi.org/10.1016/j.jcms.2011.04.014>
  18. Van hede D, Liang B, Anania S, *et al.* 3D-printed synthetic hydroxyapatite scaffold with *in silico* optimized macrostructure enhances bone formation *in vivo*. *Adv Funct Mater* 2022; 32: 2105002. <https://doi.org/10.1002/adfm.202105002>
  19. Brachet A, Belzek A, Furtak D, *et al.* Application of 3D printing in bone grafts. *Cells* 2023; 12: 859. <https://doi.org/10.3390/cells12060859>
  20. Zhang F, Yang J, Zuo Y, *et al.* Digital light processing of  $\beta$ -Tricalcium phosphate bioceramic scaffolds with controllable porous structures for patient specific craniomaxillofacial bone reconstruction. *Mater Des* 2022; 216: 110558. <https://doi.org/10.1016/j.matdes.2022.110558>
  21. Mayfield CK, Ayad M, Lechtholz-Zey E, *et al.* 3D-printing for critical sized bone defects: Current concepts and future directions. *Bioeng* 2022; 9: 680. <https://doi.org/10.3390/bioengineering9110680>
  22. Carlisle P, Guda T, Silliman DT, *et al.* Localized low-dose RbBMP-2 is effective at promoting bone regeneration in mandibular segmental defects. *J Biomed Mater Res Appl Biomater* 2019; 107: 1491–1503. <https://doi.org/10.1002/jbm.b.34241>
  23. Lu H, Liu Y, Guo J, *et al.* Biomaterials with antibacterial and osteoinductive properties to repair infected bone defects. *Int J Mol Sci* 2016; 17: 334. <https://doi.org/10.3390/ijms17030334>
  24. Prasad S, Wong RCW. Unraveling the mechanical strength of biomaterials used as a bone scaffold in oral and maxillofacial defects. *Oral Sci Int* 2018; 15: 48–55. [https://doi.org/10.1016/S1348-8643\(18\)30005-3](https://doi.org/10.1016/S1348-8643(18)30005-3)
  25. Bouakaz I, Drouet C, Grossin D, Cobraiville E, Nolens G. Hydroxyapatite 3D-printed scaffolds with Gyroid-Triply Periodic Minimal Surface (TPMS) porous structure: Fabrication and an *in vivo* pilot study in sheep. *Acta Biomater* 2023; 170: 580–595. <https://doi.org/10.1016/j.actbio.2023.08.041>
  26. Seyfer AE, Hansen JE. Facial trauma. In Moore EE, Feliciano DV, Mattox KL (eds.). *Trauma*. Fifth Edition. McGraw-Hill Professional 2003; 423–24. ISBN 0-07-137069-2.
  27. Munter DW, McGurk TD. Head and facial trauma. In Knoop KJ, Stack LB, Storrow AB (eds.). *Atlas of emergency medicine*. New York: McGraw-Hill, Medical Publishing Division 2002; 9–10. ISBN 0-07-135294-5.
  28. Jordan JR, Calhoun KH. Management of soft tissue trauma and auricular trauma. In Bailey BJ, Johnson JT, Newlands SD, *et al.* (eds.). *Head & Neck Surgery: Otolaryngology*. Hagerstown, MD: Lippincott Williams & Wilkins 2006; 935–36. ISBN 0-7817-5561-1.
  29. Neuman MI, Eriksson E. Facial trauma. In Fleisher GR, Ludwig S, Henretig FM. *Textbook of Pediatric Emergency Medicine*. Hagerstown, MD: Lippincott Williams & Wilkins 2006; ISBN 0-7817-5074-1. Retrieved 2008-10-19.
  30. Kellman RM. Commentary on Seyfer AE, Hansen JE 2003; 442.
  31. AlAli MA, Ibrahim HHH, Algharib A, Alsaad F, Rajab B. Characteristics of pediatric maxillofacial fractures in Kuwait: A single-center retrospective study. *Dental Traumatol* 2021; 37 (4): 557–561. <https://doi.org/10.1111/edt.12662>
  32. Allsop D, Kennett K. Skull and facial bone trauma. In Nahum AM, Melvin J (eds.). *Accid Injury: Biomechanics and prevention*. Berlin: Springer 2002; 254–258. ISBN 0-387-98820-3.
  33. Shapiro AJ, Johnson RM, Miller SF, McCarthy MC. Facial fractures in a level I trauma centre: The importance of protective devices and alcohol abuse. *Injury* 2001; 32 (5): 353–56. [https://doi.org/10.1016/S0020-1383\(00\)00245-X](https://doi.org/10.1016/S0020-1383(00)00245-X)
  34. Adeyemo WL, Ladeinde AL, Ogunlewe MO, James O. Trends and characteristics of oral and maxillofacial injuries in Nigeria: A review of the literature. *Head Face Med* 2005; 1 (1): 7. <https://doi.org/10.1186/1746-160X-1-7>
  35. Hunt JP, Weintraub SL, Wang YZ, Buechter KJ. Kinematics of trauma. In Moore EE, Feliciano DV, Mattox KL (eds.). *Trauma*. Fifth Edition. McGraw-Hill Professional 2003; 149. ISBN 0-07-137069-2.
  36. Sharaf Aldeen HMA, Al-Rahbi LM, Al-Ashwal AA, Abbas AMA, Al-Kibsi TAM, Al-Shamahy HA. Analysis of hardware removal in maxillofacial trauma: A retrospective study in a military hospital in Sana'a, Yemen. *Universal J Pharm Res* 2023; 8(6):46-51. <https://doi.org/10.22270/ujpr.v8i6.1039>
  37. Kent JN, Zide MF, Kay JF, Jarcho M. Hydroxylapatite blocks and particles as bone graft substitutes in orthognathic and reconstructive surgery. *J Oral Maxillofac Surg* 1986; 44: 597–605. [https://doi.org/10.1016/s0278-2391\(86\)80069-6](https://doi.org/10.1016/s0278-2391(86)80069-6)

38. Rosen HM, McFarland MM. The biologic behavior of hydroxyapatite implanted into the maxillofacial skeleton. *Plast Reconstr Surg* 1990; 85: 718–723.  
<https://doi.org/10.1097/00006534-199005000-00011>
39. Verbist M, Dubron K, Bila M, Jacobs R, Shaheen E, Willaert R. Accuracy of surgical navigation for patient-specific reconstructions of orbital fractures: A systematic review and meta-analysis. *J Stomatol Oral Maxillofac Surg* 2023; 125: 101683.  
<https://doi.org/10.1016/j.jormas.2023.101683>
40. Scolozzi P. Maxillofacial reconstruction using polyetheretherketone patient-specific implants by 'Mirroring' computational planning. *Aesthetic Plast Surg* 2012; 36: 660–665.  
<https://doi.org/10.1007/s00266-011-9853-2>
41. Verbist M, Vandeveld AL, Geusens J, Sun Y, Shaheen E, Willaert R. Reconstruction of craniomaxillofacial bone defects with 3D-printed bioceramic implants: Scoping review and clinical case series. *J Clin Med* 2024; 13: 2805.  
<https://doi.org/10.3390/jcm13102805>
42. Kauke-Navarro M, Knoedler L, Knoedler S, Deniz C, Safi AF. Surface modification of PEEK implants for craniofacial reconstruction and aesthetic augmentation-fiction or reality? *Front Surg* 2024; 28;11:1351749.  
<https://doi.org/10.3389/fsurg.2024.1351749>
43. Dubey S, Perti S, Shetty G, Shakeel SK, Gouthami K, Rajesh D. Comparison analysis of poly ether ketone and poly methyl metha acrylate used in prosthodontia for dentures: Original research. *Int J Health Sci* 2022; 6(S5), 10221–10227. <https://doi.org/10.53730/ijhs.v6nS5.12143>
44. Henrique H, Fernanda BDJBL, Shirinbak I, *et al.* The impact of 3D printing on oral and maxillofacial surgery. *J 3D Printing Med* 2023; 7:2, 3DP007.  
<https://doi.org/10.2217/3dp-2022-0025>