



RESEARCH ARTICLE

WOUND HEALING ACTIVITY OF *JATROPHA TANJORENSIS* LEAVES

Madepalli Byrappa Gowdu Viswanathan¹ , Jesu Doss Jeya Ananthi^{2*} , NataRajan Livingston Raja² ,
 Narayanan Venkateshan² 

¹Department of Plant Science, Bharathidasan University, Tiruchirappalli 620 024, Tamil Nadu, India.

²Department of Pharmaceutics, Arulmigu Kalasalingam College of Pharmacy, Krishnankoil – 626126, Tamil Nadu, India.

Article Info:

Abstract



Article History:

Received: 1 August 2018
 Reviewed: 16 September 2018
 Accepted: 28 October 2018
 Published: 15 November 2018

Cite this article:

Viswanathan MBG, Ananthi JDJ, Raja NRL, Venkateshan N. Wound healing Activity of *Jatropha tanjorensis* Leaves. Universal Journal of Pharmaceutical Research 2018; 3(4): 21-26. <https://doi.org/10.22270/ujpr.v3i5.198>

*Address for Correspondence:

Dr. J. Jeya Ananthi, Department of Pharmaceutics, Arulmigu Kalasalingam College of Pharmacy, Krishnankoil – 626126, Tamil Nadu, India.
 E-mail: jeyaananthi2005@yahoo.co.in

Objective: The term “wound” is defined as a disruption of normal anatomical structure. Therefore, “healing” is the complex and dynamic process that results in the restoration of anatomical continuity and function.

Methods: Albino Wistar rats (150-180 g) of both sexes were selected. The experiment of Wound Healing Activity by Excision Wound Model and Incision Wound Model by the simple ointment B.P., reference standard drug (0.2% w/w nitrofurazone ointment), stigmaterol ointment (0.2% w/w), hexane, chloroform and methanol extract ointments of 3%, 4% and 5% w/w of leaves in *Jatropha tanjorensis* in simple ointment base (where 3g, 4g and 5 g of the extracts was incorporated in 100 g of simple ointment separately).

Results: The time for wound closure to methanol extract ointment (5% w/w) and stigmaterol (0.2% w/w) was similar to that of standard drug, nitrofurazone ointment (0.2% w/w) 16±2 days in Excision Wound Model. The significant tensile strength at 3%: 4%: 5% w/w methanol extract ointments ($p < 0.001$), followed by chloroform extract and hexane extract. Stigmaterol ointment at 0.2% w/w produced tensile strength comparable with Standard drug, nitrofurazone ointment (0.2% w/w) ($p < 0.001$) in Incision Wound Model.

Conclusion: Juice of the *Jatropha* plant and the pounded leaves are applied to wounds and refractory ulcers. The juice is very successfully used to treat scabies, eczema and ringworm. The present study proved that the leaves have wound healing activity.

Keywords: Excision, incision wound *Jatropha tanjorensis*, leaves, wound healing.

INTRODUCTION

The genus *Jatropha* belongs to tribe Joanneasiae of Crotonoideae in the *Euphorbiaceae* family and contains approximately 175 species, cultivated throughout the tropical to temperate regions of the world. The name is derived from the Greek words *ιατρός* (*iatros*), meaning “physician,” and *τροφή* (*trophe*), meaning “nutrition” as food. Homeopathically it is used for cold sweats, colic, collapse cramps, cyanosis, diarrhea, and leg cramps. The root, stem, leaves, fruit, seed, bark and latex of the plant are largely used for the treatment of many diseases in different parts of the world¹. The juice of the plant and the pounded leaves are applied to wounds and refractory ulcers. The juice is very successfully used to treat scabies, eczema and ringworm². Leaves are regarded as antiparasitic, applied to scabies, rubefacient for paralysis, rheumatism; also applied to hard tumors³. According to Ochse⁴, “The young leaves may be safely eaten, steamed or stewed”. They are

favoured for cooking with goat meat, said to counteract the peculiar smell. It is reported to be abortifacient, anodyne, antiseptic, cicatrizant, depurative, diuretic, emetic, hemostatic, lactagogue, narcotic, purgative, rubefacient, styptic, vermifuge, and vulnerary^{5,6}. Latex is applied topically to bee and wasp stings⁷ and to dress sores and ulcers and inflamed tongues⁸. Duke and Wain⁶ list it for homicide, piscicide, and raticide as well. Colombians drink the leaf decoction for venereal disease⁹. The latex was strongly inhibitory to watermelon mosaic virus¹⁰. *Jatropha tanjorensis*¹¹ Shrubs, 3-4 m high; stem long, stout, dichotomously branched; branches puberulous when young, glabrous when mature.

Distribution

India: Tiruchirappalli, Pudukottai, Thanjavur and Ramanathapuram Districts in Tamil Nadu and Pondicherry.

West Africa including Nigeria: Weed of field crops, bush re-growth, roadside and disturbed places in the higher rainfall zones. The aim of the present study is to

study the wound healing effects of leaves of *Jatropha tanjorensis* against Excision Wound and Incision Wound in rats. This plant has not been studied for their wound healing effect.

MATERIALS AND METHODS

Plant Material

Leaves of *Jatropha tanjorensis* were collected in the vicinity of Pondicherry. An authentic herbarium specimen (MBV and JJ 14774) was prepared and deposited in the Herbarium of the Centre for Research and Development in Siddha-Ayurveda Medicines (CRDSAM), Department of Plant Science, Bharathidasan University, Tiruchirappalli 620 024, Tamil Nadu, India, for reference.

Preparation of plant extracts

The collected plants were dried at room temperature, pulverized by a mechanical grinder, sieved through 40 mesh. The powdered materials were extracted with hexane, chloroform and methanol using Soxhlet extraction apparatus. The chloroform and methanolic extract was then concentrated and dried under reduced pressure. The methanol free semi-solid mass thus obtained was used for the experiment¹².

Pharmacology

Toxicity of both the extracts and isolated compounds (Friedelin, β -amyrin, stigmasterol and R-(+)-4-hydroxy-2-pyrrolidinone) was fixed for biological evaluation following the Organization for Economic Cooperation and Development (OECD) guidelines (2001). LD₅₀ values were calculated with no sign of acute toxicity at >2000 mg/kg for the extracts and 10 mg/kg for the isolated compounds. Animal studies were performed with the approval of the Institutional Animal Ethics Committee (IAEC) in Arulmigu Kalasalingam College of Pharmacy, Krishnan Koil 626126 (Reg. No. 509/01/C/CPCSEA - Committee for the Purpose of Control and Supervision on Experimental Animals, Department of Animal Welfare, Government of India (No. 412). Experimental animals housed under standard conditions were fed with standard diet (Lipton India Ltd., Bangalore) and water *ad libitum* in the Animal House, and maintained at room temperature under suitable nutritional and environmental conditions throughout the experiment. Fine chemicals were purchased from Sigma-Aldrich, St. Louis, MO 63103, and S.D. Fine Chemicals, Mumbai, India, and other chemicals from SISCO Research Laboratories Pvt. Ltd., Mumbai, India.

Wound Healing Activity

Excision Wound Model

Albino Wistar rats (150-180 g) of both sexes were selected to carry out the experiment. Twelve groups of 6 animals in each group were anaesthetized with ether. The rats were depilated at the back and a predetermined area of 500 mm² full thickness skin was excised at the dorsal interscapular region. Rat wounds were left undressed to the open environment. This model was used to monitor wound contraction and epithelization time. The simple ointment B.P., reference standard drug (0.2% w/w nitrofurazone ointment), stigmasterol ointment (0.2% w/w), hexane,

chloroform and methanol extract ointments of 3%, 4% and 5% w/w in simple ointment base (where 3g, 4g and 5 g of the extracts was incorporated in 100 g of simple ointment separately) were applied everyday till the wound was completely healed. The progressive changes in wound area were monitored planimetrically by tracing the wound margin on a graph paper every alternate day. The changes in healing of wound, i.e., the measurement of wound area on graph paper were expressed as unit (mm²). Wound contraction was expressed as percentage reduction of original wound size^{13,14}.

Incision Wound Model

Twelve groups of 6 animals in each group were taken and anaesthetized under light ether anesthesia. The incision wound^{13,14} with one full thickness paravertebral incision of 6 cm length was made including the cutaneous muscles of the depilated back of each rat. Full aseptic measures and no local or systemic antimicrobials were not used throughout the experiment. After incision, the parted skin was kept together and stitched with sutures, 1 cm apart. The continuous threads on both wound edges were tightened for good adaptation of wound and it was left undressed. The ointment of all the extracts 3%, 4% and 5% w/w, stigmasterol ointment (0.2% w/w), standard drug (nitrofurazone ointment) and simple ointment B.P. were applied to the wound twice daily, until complete recovery to the respective groups of animals^{15,16}.

Measurement of Healing

On the 9th day after wounding, the sutures were removed and tensile strength was measured on 10th day. For measuring the tensile strength, the rats were again anesthetized and each rat was placed on a stack of towels at the middle of the board. The amount of the towels could be adjusted in such a way so that the wound was at the same level as the tips of the arms. The clamps were then carefully clamped on the skin of the opposite edges of the wound. The longer pieces of the fishing line were placed on the pulley and finally to the polyethylene bottle. The position of board was adjusted to rate water from a large reservoir, until the wound began to open. The amount of water in the polyethylene bottle was weighed and equated as the tensile strength of the wound. The tensile strength induced by the extracts, stigmasterol ointment (0.2% w/w), and the nitrofurazone ointment-treated wounds was compared with Control.

RESULTS

Excision Wound Model

Wound area (mm²) and the percentage of wound contraction produced by different extract ointments (3%: 4%: 5% w/w) were respectively such as 12±10.30; 97.69%: 10±8.40; 98.06%: 9±6.20; 98.07% ($p<0.001$) to methanol extract ointment and 8.9±5.6; 99.00% ($p<0.001$) to stigmasterol (0.2% w/w) on 16th day; and 10±0.40; 98.11%: 9±0.30; 98.29%: 7±0.20; 98.66% to hexane extract and 9±0.70; 98.30 %: 8±0.40%; 98.48%: 6±0.20; 98.85% to chloroform extract on 18th day. The time for wound closure to

methanol extract ointment (5% w/w) and stigmasterol (0.2% w/w) was similar to that of standard drug, nitrofurazone ointment (0.2% w/w) 16±2 days (Table 1; Figure 1).

Incision Wound Model

The sutures were removed and measured tensile strength (in g±SEM) at 3%: 4%: 5% w/w of different extract ointments was 578±10.20: 581±10.40: 584±10.90 ($p<0.001$) to methanol extract, 528±9.50:

532± 9.70: 535±10.10 to chloroform extract and 519±9.60: 521±9.80: 526±10.00 ($p<0.001$) to hexane extract. Stigmasterol ointment at 0.2% w/w produced tensile strength of 591±14.60 ($p<0.001$). Standard drug, nitrofurazone ointment (0.2% w/w) produced significant increase of tensile strength such as 597±14.80 ($p<0.001$) (Table 2; Figure 2).

Table 1: Effect of various solvent extract of leaves and stigmasterol ointment on excision wounds.

Treatment	Dosage	Wound area (mm ²) (% of wound contraction)					
		Post wounding days					
		0 day	4 th day	8 th day	12 th day	16 th day	18 th day
Control	2% w/w	521±20.00 (0.00)	458±13.50 (11.10)	368±14.10 (28.10)	278±13.30 (44.10)	207±10.80 (59.60)	179±13.80 (63.70)
Nitrofurazone ointment	0.2% w/w	512±38.80 (0.00)	333±18.40 (34.50)	102±9.70* (79.70)	30±2.00* (94.00)	0.00* (100.00)	0.00* (100.00)
Hexane extract	3% w/w	531±24.20 (0.00)	463±18.70 (12.80)	288±17.60 (45.76)	105±12.80 (80.18)	31±6.70 (94.16)	10±0.40 (98.11)
	4% w/w	528±23.40 (0.00)	461±20.60 (12.68)	282±15.20 (46.59)	100±10.60 (62.10)	29±4.60 (94.50)	9±0.30 (98.29)
	5% w/w	523±22.30 (0.00)	457±18.20 (12.60)	279±13.90 (46.65)	99±8.40 (80.90)	26±2.50 (95.02)	7±0.20 (98.66)
Chloroform Extract	3% w/w	532±23.20 (0.00)	455±18.60 (14.47)	276±13.60 (48.12)	100±8.20 (81.20)	25±2.20 (94.17)	9±0.70 (98.30)
	4% w/w	529±22.60 (0.00)	453±18.20 (14.36)	273±13.30 (48.39)	99±7.60 (81.28)	28±2.40 (94.70)	8±0.4 (98.48)
	5% w/w	524±21.80 (0.00)	449±12.80 (14.31)	269±12.80 (48.66)	96±7.40 (81.56)	31±2.60 (95.22)	6±0.20 (98.85)
Methanol Extract	3% w/w	521±38.40 (0.00)	323±16.20 (38.00)	197±14.20 (62.18)	82±8.20 (84.26)	12±10.3 (97.69)	0.00 (100.00)
	4% w/w	518±37.20 (0.00)	320±14.40 (38.22)	194±13.30 (62.54)	79±8.20 (84.74)	10±8.4 (98.06)	0.00 (100.00)
	5% w/w	515±36.70 (0.00)	316±12.40 (38.64)	191±11.20 (62.91)	77±5.90 (83.88)	9±6.20 (98.07)	0.0* (100.00)
Stigmasterol	0.2% w/w	513±35.70 (0.00)	309±13.40 (37.80)	178±10.50 (57.80)	69±5.20* (85.30)	8±5.60* (99.00)	0.00* (100.00)

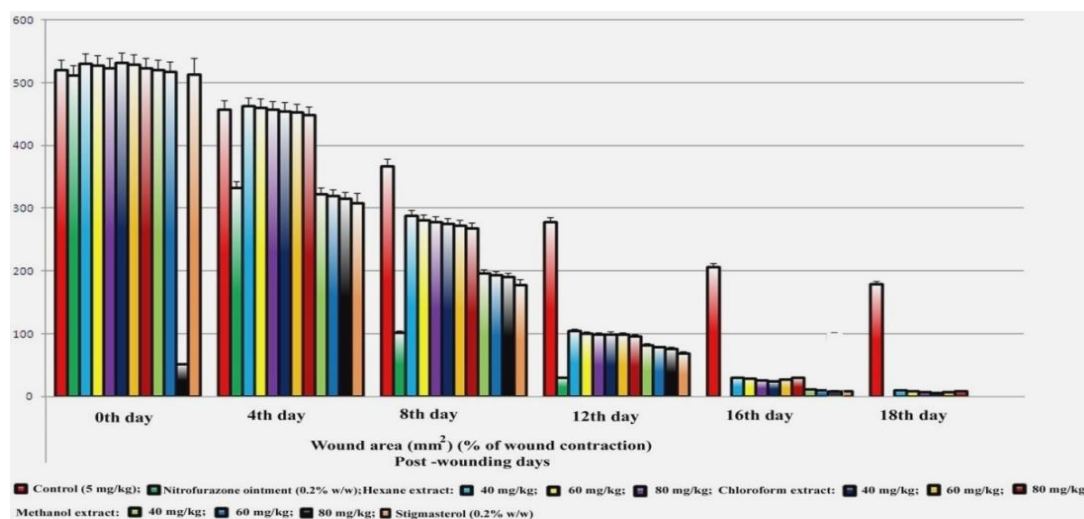


Figure 1: Effect of various solvent extracts of leaves and stigmasterol ointment on excision wounds.

DISCUSSION

The term “wound” is defined as a disruption of normal anatomical structure and more importantly function. Therefore, “healing” is the complex and dynamic process that results in the restoration of anatomical

continuity and function¹⁷. Acute wounds normally heal in a very orderly and efficient manner characterized by four distinct but overlapping phases such as hemostasis, inflammation, proliferation and remodeling¹⁸. These steps are orchestrated in a controlled manner by a variety of bioactive molecules

like growth factors, cytokines, their receptors and matrix molecules¹⁹. Such a controlled phenomenon can be disrupted in diseases like diabetes, immunocompromised persons, ischemia, etc., thus leading to the development of a chronic wound. Prolonged or incomplete wound healing is then a troublesome complication²⁰.

Excision Wound Model

Nath and Dutta²¹ isolated the protease namely curcain from the latex of *J. curcas* and reported its effective wound healing property by excision wound model in mice. Ointments of 0.5% and 1.0% (w/w) curcain were compared with 0.2% (w/w) nitrofurazone ointment and 0.15% (w/w) propamide isethionate cream. Curcain ointments healed the wound completely within 10 days of treatment whereas the nitrofurazone ointment and propamide isethionate cream took 15 and 20 days respectively to show the same results.

Table 2: Effect of various solvent extracts of leaves and stigmaterol ointment on incision wounds in *J. tanjorensis*.

Treatment	Dosage % w/w	Tensile strength (g)
Control	2	432.00±13.30
Nitrofurazone	0.2	597.00±14.80*
Hexane extract	3	519.00±9.60
	4	521.00±9.80
	5	526.00±10.00*
Chloroform extract	3	528.00±9.50
	4	532.00±9.70
	5	535.00±10.10
Methanol extract	3	578.00±10.20*
	4	581.00±10.40*
	5	584.00±10.90*
Stigmaterol	0.2	591.00± 14.60*

Values are S.E.M. of six animals of each group; $P < 0.001$ Vs Control by Student "t" test

Esimone et al.,²² tested ointments at 0.5 g/10 g, 1 g/10 g and 1.5 g/10 g of the methanol leaf extract in *J. curcas*, standard gentamycin and blank ointment on the excision wound in rats and their respective wound area on 21 day was 1.33±0.07, 0.2±0.03, 0.00±0.00, 0.00±0.00, and 3.90±0.28 and epithelization period was 17.80±0.84, 17.00±0.71, 14.80±0.45, 14.60±0.90 and 18.80±0.84. Methanol leaf extract ointments 1 g/10 g and 1.5 g/10 g and gentamycin showed significantly higher rate of wound healing ($P < 0.05$) and reduced epithelization period. The results in the present study showed respective wound area and the percentage of wound contraction for the methanol leaf extract ointments at 3% w/w: 4% w/w: 5% w/w as 12±10.30; 97.69%: 10±8.40; 98.06%: and 8.9±5.6; 99.00% ($p < 0.001$) on 16th day and 9±0.70; 98.30%: 8±0.40%; 98.48%: 6±0.20; 98.85% to chloroform extract and 10±0.40%; 98.11: 9±0.30; 98.29%: 7±0.20; 98.66% to hexane extract on 18th day. Stigmaterol (0.2% w/w) produced 9±6.2; 98.07% ($p < 0.001$) on 16th day. The standard drug, nitrofurazone ointment (0.2% w/w) produced 0.00; 100% on 16th day. The time for wound closure to methanol extract ointment (5% w/w) and stigmaterol (0.2% w/w) was similar to that of nitrofurazone ointment (0.2% w/w) 16±2 days. The

results suggested that topical application of the test drugs in animals significantly enhanced the rate of wound healing as assessed by wound area and the percentage of wound contraction. The time of wound closure for the ointments was observed such as 14±2 days to standard drug, 16±2 days to methanol extract and stigmaterol, 18±2 days to chloroform and hexane extract in a dose-dependent manner. Increasing the concentration of the extract is directly proportionate to the increase in wound contraction percentage (Table 1; Figure 1). Treated excision wounds showed an increased rate of wound contraction, leading to faster healing as confirmed by the increased wound healing area compared to control.

Incision wound model

Tensile strength for control was 432±13.30 g (Table 2; Figure 2). The increased tensile strength was 591±14.60 g, 584±10.90 g, 535±10.10 g and 526±10.00 g for stigmaterol, methanol, chloroform and hexane extracts (5% w/w) respectively. While the standard ointment-treated group showed 597±14.80 g. At 4% and 3% w/w, the extracts showed decreased tensile strength such as 581±10.40 g and 578±10.20 g to methanol extract, 532±9.70 g and 528±9.50 g to chloroform extract and 521±9.80 g and 519±9.60 g to hexane extract. It is well-accepted that several local growth factors help in the wound healing process. It is possible that the test extracts may have a growth factor-like activity or have the ability to stimulate the expression of growth factors like the basic fibroblast growth factor (bFGF). The bFGF has the broadest range of target cells such as endothelial cells, fibroblasts, myoblasts, etc²³. Wound contraction is mediated by specialized myofibroblasts found in the granulated tissue²⁴. The increase in tensile strength of treated wounds may be due to increase in collagen concentration and stabilization of the fibers^{13,25}.

Excision and Incision Wound Models

Shetty et al.,²⁶ recorded very effective property to accelerate wound healing process to the crude bark extract of *J. curcas* in Wistar albino rats. Odoh et al.,²⁷ reported the wound healing property of methanol leaf extract in *J. curcas* by incision and excision wound models in rats. The wound healing effect at 200 mg/kg was compared to that of standard, cicatrin, and showed significant healing potential ($P < 0.05$) in dose-dependent manner for the increase in wound contraction rate and skin breaking strength and decrease in epithelization period. Further, secondary infections by microbes in the wounds may further aggravate the conditions. Some of the important organisms include *Staphylococcus aureus*, *Streptococcus pyogenes*, *Corynebacterium* species, *Escherichia coli* and *P. aeruginosa* wherein the most common are *Staphylococcus aureus* and β -hemolytic *Streptococcus* species²⁸ which are considered as "transient flora" of the skin²⁹. *P. aeruginosa* is the predominant organism, which causes air-borne infection and its frequency of infection is more in burn patients. Infected wounds heal more slowly and have an increased incidence of scarring³⁰. Mycotic infections are also an important etiology of these infections, most of them are caused by dermatophytes

and other related fungi. A wide range of antibiotics are being used at present for healing wounds and for treating wound infections but they are now proved to have adverse effects in the human body. In view of these developments, so much of attention has been paid recently to the extracts of biologically active compounds isolated from plant species used in herbal medicinal system³¹. Pro-inflammatory cytokines were implicated to stimulate the synthesis of platelet activating factors by the recruited monocytes which in

turn induce several angiogenic factors and chemokines³². Moon *et al.*,³³ reported the pronounced improvement of type-I collagen material invasion by β -sitosterol which acts as an angiogenic factor in wound healing. Angiogenesis is the growth of new vascular capillary channels from pre-existing vessels and is of fundamental importance in a number of physiological processes such as embryonic development, reproduction, wound healing and bone repair³⁴.

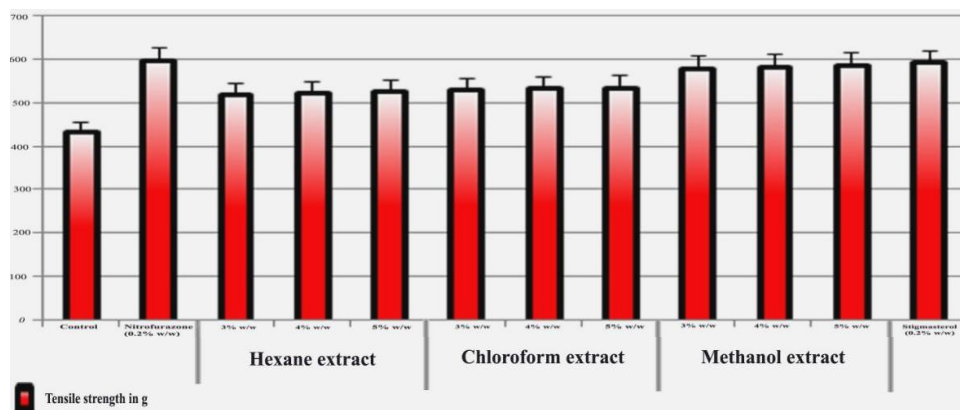


Figure 2: Effect of various solvent extracts of leaves and stigmasterol ointment on incision wounds.

When wounding occurs it is accompanied within quite a short time by pain, reddening and edema of the surrounding tissue. These are all classical symptoms of inflammation and are caused by the release of the eicosanoids, prostaglandins and leukotrienes and of ROS. The release of other factors such as the cytokines is also important which is caused by neutrophils aggregating at the wound site and producing proteolytic enzymes and ROS. Apart from the role of antioxidants in removing products of inflammation, they are also beneficial in wound healing in some other means. Because of these factors, overall antioxidant effects appear to be important in the successful treatment of wounds³⁵. In the present study, the test extracts were shown to be strongly antioxidant due to the presence of flavonoids and polyphenols. Infected wounds heal less rapidly and also often result in the formation of unpleasant exudates and toxins that will be produced with concomitant killing of regenerating cells³⁵. *Staphylococcus aureus*, *Streptococcus pyogenes* and *P. aeruginosa* are the most common wound pathogens with $\geq 10^3$ CFU/g tissues which were classified as infection³⁶. The presence of saponins, flavonoids and other phenolics in the test extracts and their potent polyvalent activity due to their anti-inflammatory, antioxidant and antimicrobial properties could have contributed to the wound healing because of their detergent ability to remove grease, dirt and bacteria^{37,38}.

CONCLUSIONS

The time for wound closure to methanol extract ointment (5% w/w) and stigmasterol (0.2% w/w) is similar to that of nitrofurazone ointment (0.2% w/w) 16 ± 2 days and 18 ± 2 days to chloroform and hexane

extract in a dose-dependent manner. Activity is in the order of stigmasterol, methanol, chloroform and hexane extracts (5% w/w) respectively. Test extracts exhibit potent anti-inflammatory and antioxidant activities due to the presence of flavonoids and polyphenols which could have contributed wound healing in part; and Activity against *Candida albicans* indicates healing capacity of superficial skin infection.

ACKNOWLEDGEMENTS

The authors thank Illayavallal Dr. K. Sridharan, Chairman, Arulmigu Kalasalingam College of Pharmacy for providing necessary laboratory facilities for carrying out the present research work.

AUTHOR'S CONTRIBUTION

Viswanathan MBG: writing original draft, methodology. **Ananthi JDJ:** writing, review and editing, methodology. **Raja NRL:** writing, review, and editing, methodology. **Venkateshan N:** writing, review, and editing. The final manuscript was read and approved by all authors.

DATA AVAILABILITY

The datasets used and/or analyzed during the current study are available from the corresponding author on reasonable request.

CONFLICT OF INTEREST

No conflict of interest associated with this work.

REFERENCES

- Rajore S, Batra A. *Jatropha curcas* L: a plant of immense potential Value. *J Econ Tax Bot* 2003; 27: 36-41. <https://doi.org/10.1016/j.fitote.2012.07.007>
- Kirtikar KR, Basu BD. *Indian Medicinal Plants*, Oriental Enterprises, Dehradun, India. 2001; 2nd edn, Vols. I-4.
- Hartwell JL. *Plants used against cancer; a survey 1969*; Lloydia 32: 153-205. PMID: 5173435
- Ochse JJ, 1931. *Vegetables of the Dutch East Indies*. Reprinted 1980. A. Asherand Co., BV Amsterdam.
- List PH, Horhammer L. 1969-1979. *Hager's handbuch der pharmazeutischen praxis*. Vols 2-6. Springer-Verlag, Berlin. <https://doi.org/10.1007/978-3-642-57993-6>
- Duke JA, Wain KK. *Medicinal plants of the world*. Computer index with more than 85,000 entries. Three Volumes, Longman Group, UK Limited, UK, 1981. <https://doi.org/10.12691/wjar-7-2-1>
- Watt JM, Breyer-Brandwijk MG. *The medicinal and poisonous plants of southern and eastern Africa*. 2nd edn. E. and S. Livingstone, Ltd., London, 1962.
- Perry LM. *Medicinal plants of East and Southeast Asia*. MIT Press, Cambridge, 1980.
- Morton JF, 1981. *Atlas of medicinal plants*. C.C. Thomas, Springfield, IL.
- Tewari JP, Shukla IK. Inhibition of infectivity of 2 strains of watermelon mosaic virus by latex of some angiosperms. *Geobios*. 1982; 9: 124-126.
- Ellis JL, Saroja J. *Bombay Nat Hist Soc*. 1962; 58: 834.
- Harborne JB. *Phytochemical Methods*, 2nd Edition, Chapman and Hall, London, 1998. <https://doi.org/10.1007/978-94-009-5570-7>
- Udupa SL, Udupa AL, Kulkarni DR. Anti-inflammatory and wound healing properties of *Aloe vera*. *Fitoterapia*. 1994; 65: 141-145. PMID: 23181083
- Saha K, Mutherjea PK, Das J, Pal M, Saha BP. Wound healing activity of *Leucas lavandulaefolia* Rees. *J Ethnopharmacol* 1997; 56: 139-144. [https://doi.org/10.1016/S0378-8741\(97\)01522-5](https://doi.org/10.1016/S0378-8741(97)01522-5)
- Udupa SL, Udupa AL, Kulkarni DR. Studies on the anti-inflammatory and wound healing properties of *Maringa oleifera* and *Aegle marmelos*. *Fitoterapia* 1994; 65: 119-123. <https://doi.org/10.3390/ijerph15112360>
- Jaswanth A, Akilandeswari S, Loganathan V, Manimaran S, and Ruckmani K. Wound Healing activity of *Aegle marmelos*. *Indian J Pharm Sci* 2001; 63: 41-44.
- Lazarus GS, Cooper DM, Knighton DR, et al. Definitions and guidelines for assessment of wounds and evaluation of healing. *Arch Dermatol* 1994; 130: 489-493. <https://doi.org/10.1046/j.1524-475X.1994.20305.x>
- Diegelmann RF, Evans MC. Wound healing: an overview of acute, fibrotic and delayed healing. *Front Biosci* 2004; 9: 283-289. <https://doi.org/10.2741/1184>
- Shukla A, Rasik AM, Jain GK, Shankar R, Kulshrestha DK, Dhawan BN. *In vitro* and *in vivo* wound healing activity of asiaticoside isolated from *Centella asiatica*. *J Ethnopharmacol* 1999;65:1-11. [https://doi.org/10.1016/S0378-8741\(98\)00141-X](https://doi.org/10.1016/S0378-8741(98)00141-X)
- Ingold WM. Wound therapy: growth factors as agents to promote healing. *Trends Biotechnol* 1993; 11: 387-392. [https://doi.org/10.1016/0167-7799\(93\)90098-T](https://doi.org/10.1016/0167-7799(93)90098-T)
- Nath LK, Dutta SK. Wound healing responses of the proteolytic enzyme curcain. *Indian J Pharmacol* 1992; 24: 114-115. <https://doi.org/10.22270/ujpr.v3i5.198>
- Esimone CO, Nworu CS, Jackson CL. Cutaneous wound healing activity of a herbal ointment containing the leaf extract of *Jatropha curcas* L. (*Euphorbiaceae*). *Int J Appl Res Nat Prod* 2009; 1: 1-4.
- Scott AC. Laboratory control of antimicrobial therapy. In: Colle JG, Duguid JP, Fraser AG, and Marmion BP, (Eds.) Mackie and McCartney Practical Medical Microbiology, 13th ed, Volume 2. Churchill Livingstone: Edinburgh. Schweigerer, L. 1988. Basic fibroblast growth factor as wound healing hormone. *Trends Pharm* 1989; 9: 427-428.
- Moulin V, Auger FA, Garel D, Germain, L. Role of wound healing myofibroblasts on re-epithelization of human skin. *Burns* 2000; 26: 3-12. <https://doi.org/10.1016/j.retram.2016.09.003>
- Udupa AL, Aithal KS, Sharma SP, Vasanth Kumar Kulkarni DR, Rajgopal PK, Srinivasan KK. Anti-inflammatory and wound healing activity of the crude alcoholic extract and flavonoids from *Vitex lucoxylo*. *Fitoterapi* 2005; 11: 263-265. <https://doi.org/10.1016/j.biopha.2018.12.075>
- Shetty S, Udupa S, Udupa L, Somayaji N. Wound healing activity of *Ocimum sanctum* Linn with supportive role of antioxidant enzymes. *Indian J Physiol Pharmacol* 2006; 50: 163-168. PMID: 17051736
- Oboh FOJ, Masodje HI. Nutritional and Antimicrobial Properties of *Vernonia amygdalina* Leaves. *Int J Biomed Health Sci* 2009; 5: 51-56.
- Mertz PM, Ovington LG. Wound healing Microbiology. *Dermatol Clin* 1993; 11:739-747. <https://doi.org/10.1128/CMR.14.2.244-269.2001>
- Bikowski J. Secondarily infected wounds and dermatoses: a diagnosis and treatment guide. *J Emerg Surg* 1999; 17: 197-206. [https://doi.org/10.1016/S0736-4679\(98\)00150-4](https://doi.org/10.1016/S0736-4679(98)00150-4)
- Robson MC. Wound infection. A failure of wound healing caused by and imbalance of bacteria. *Surg Clin North Am* 1997; 77: 637-650. [https://doi.org/10.1016/s0039-6109\(05\)70572-7](https://doi.org/10.1016/s0039-6109(05)70572-7)
- Essawi T, Srour M. Screening of some Palestinian medicinal plants for antibacterial activity. *J Ethnopharmacol* 2000; 70: 343-349. [https://doi.org/10.1016/S0378-8741\(99\)00187-7](https://doi.org/10.1016/S0378-8741(99)00187-7)
- Lupia E, Montrucchio G, Battaglia E, Modena V, Camussi G. Role of tumor necrosis factor alpha and platelet activating factor in neo angiogenesis induced by synovial fluids of patients with the rheumatoid arthritis. *Eur J Immunol* 1996; 6: 1690-1694. <https://doi.org/10.1084/jem.180.1.377>
- Moon EJ, Lee YM, Lee OH, Lee MJ, Lee SK, Chung MH, Park YI, Sung CK, Choi JS, Kim, KW. A novel angiogenic factor derived from Aloe vera gel: β -sitosterol, a plant sterol. *Angiogenesis* 1999; 3: 117-123. <https://doi.org/10.1023/A:1009058232389>
- Maheswari RK, Singh AK, Gaddipati J, Srimal RC. Multiple biological activities of curcumin: A short review. *Life Sci* 2006; 78: 2081-2087. <https://doi.org/10.1016/j.lfs.2005.12.007>
- Houghton PJ, Hylands PJ, Mensah AY, Hensel A, Deters AM. *In vitro* tests and ethnopharmacological investigations: Wound healing as an example. *J Ethnopharmacol* 2005; 100: 100-107. <https://doi.org/10.1016/j.jep.2013.06.007>
- Bergstrom N, Allman RM, Alvarez OM, Bennett MA, Carlson CE, et al. Treatment of pressure ulcers. Clinical Practice Guideline No. 15, AHCPR Publication No.95-0652. Department of Health and Human Services, Public Health Services Agency for Health care Policy and Research, Rockville, M.D. U.S., 1994. <https://doi.org/10.1111/j.1524-475X.2006.00175.x>
- Houghton PJ, Mensah AY. Buddleja and wound healing. *SOFW-J* 1997; 123: 40-43. <https://doi.org/10.5772/intechopen.79179>
- Singh M, Govindarajan R, Nath V, Rawat AKS, Mehrotra S. Antimicrobial, wound healing and antioxidant activity of *Plagiochasma appendiculatum* Lehm. et Lind. *J Ethnopharmacol* 2006; 107: 67-72. <https://doi.org/10.1016/j.jep.2006.02.007>