









## RESEARCH ARTICLE

## COMPARATIVE STUDY OF THE EFFICACY OF STEM CELLS IN CORNEAL REGENERATION IN A CHEMICAL BURN IN RABBITS

Abdelkrim Salama<sup>1,2,3</sup> , Abdul-Malik Abudunia<sup>2</sup> , Ali Gamal Al-kaf<sup>4</sup> , Nabeel Muhsin Ziad<sup>5</sup> ,  
 Azeddine Ibrahimi<sup>2</sup> , Layachi Chabraoui<sup>3</sup> 

<sup>1</sup>Medically Assisted Reproduction Centre, Fez, Morocco.

<sup>2</sup>Department of Biotechnology Laboratory (Med-Biotech), Faculty of Medicine and Pharmacy, University Mohamed V, Morocco.

<sup>3</sup>Department of Biochemistry and Molecular Biology, Faculty of Medicine and Pharmacy, University Mohamed V, Morocco.

<sup>4</sup>Department of Medicinal Chemistry, Faculty of Pharmacy, Sana'a University-Yemen.

<sup>5</sup>Ministry of Public Health and Population, Yemen.

### Article Info:



#### Article History:

Received: 5 June 2020  
 Reviewed: 11 July 2020  
 Accepted: 23 August 2020  
 Published: 15 September 2020

#### Cite this article:

Salama A, Abudunia AM, Al-kaf AG, Ziad NM, Ibrahimi A, Chabraoui L. Comparative study of the efficacy of stem cells in corneal regeneration in a chemical burn in rabbits. Universal Journal of Pharmaceutical Research 2020; 5(4):47-51. <https://doi.org/10.22270/ujpr.v5i4.445>

#### \*Address for Correspondence:

**Abdelkrim Salama**, Department of Biotechnology Laboratory (Med-Biotech), Faculty of Medicine and Pharmacy, University Mohamed V, Rabat, Morocco, Tel: 0667479647.  
 E-mail: [abdelkrim.salama@um5s.net.ma](mailto:abdelkrim.salama@um5s.net.ma)

### Abstract

**Objectives:** This study compares the efficacy of stem cell transplantation in corneal regeneration and restoration of the limbic deficit in an experimental chemical burn in rabbits.

**Methods:** The biopsy of limbus and the chemical burn were performed in all rabbits, and the amniotic membranes were obtained from a pregnant rabbit. A control group without transplantation, to study spontaneous and natural healing, and transplanted the stem cells produced *in vitro* under the corneal epithelium burned. To compare the result, a group was tested for amniotic stem cell transplantation, a group for limbal stem cell graft, and another group for combined transplantation of both types of stem cells.

**Results:** Transplanted rabbits develop permanent unilateral blindness due to a severe limbic deficit. The group receiving only amniotic stem cells shows temporary anatomical improvement without functional recovery. The two groups receiving limbal stem cells alone or combined with amniotic stem cells showed anatomical and functional satisfaction with quick recovery time for the combined transplantation.

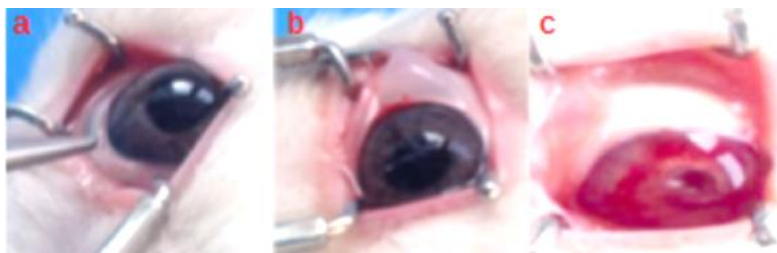**Conclusions:** A simple chemical burn can establish permanent blindness. When the limbic deficit is important, spontaneous healing is not available. Transplantation of stem cell transplant is the only way to repair this deficit and regenerate the cornea. Only limbic stem cells can be sufficient. Amniotic stem cells can support and speed up the healing time when it combined to limbal stem cells graft.

**Keywords:** Chemical burn, corneal regeneration, limbic deficit, stem cell, transplantation.

## INTRODUCTION

The ocular surface contains three adjacent epithelia: conjunctiva, limbus, and cornea. Cornea shows many roles in protecting internal structures from germs and particles and in protecting against ultraviolet rays<sup>1,2</sup>. It is the transparent part of the eye, its location on the front surface of the eyeball often exposes it to accidental injuries. All damage can lead to infectious keratitis, chronic ulcer, limbal deficiency, or even permanent blindness. Corneal blindness is the fourth leading cause of blindness in the globe according to the

World Health Organization (WHO), responsible for 5.1% cases<sup>3</sup>. Various studies confirm the therapeutic success of amniotic membrane grafting associated or not with limbal stem cells<sup>4</sup>. This success is limited in time and often linked to later complications. Current study search about most effective transplanted cells. In current study, two types of stem cells were used for corneal repair in an experimental limbal deficit in rabbits; autologous cells from the limbus and amniotic cells amplified *in vitro* and then administered as a single or combined transplant.



**Figure 1: Limbal biopsy process.**

**(a): Before biopsy (b): Immediately after biopsy (c): 1 hour after biopsy.**

## MATERIALS AND METHODS

### Drugs and chemicals

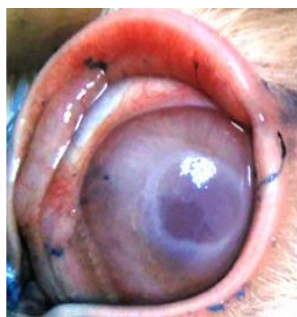The following drugs were used in the studies: Midazolam (0.5 mg/kg), Propofol (5 mg/kg); 4% hydrogen chloride, antibiotic (penicillin 10,000 µg/ml, streptomycin 10,000 µg/ml) and antifungal agent 0.1 % Nystatin. was purchased from Ibn Sina pharmacy at Rabat-Morocco<sup>5,6</sup>.

### Animals

The study was performed on adult male rabbits (1.50–2.50 kg), bred at the laboratory of Pharmacology, Faculty of Medicine and Pharmacy of Rabat. All animals were kept in a room maintained under environmentally controlled conditions of 23°C and 12 h light–12 h dark cycle. The food was withdrawn on the day before the experiment, the animals were handled according to the prescribed ethical guidelines for laboratory animals<sup>7,8</sup>. This study was conducted using the 17 Dutch rabbits as the experimental model, and one a pregnant female for amniotic membrane collection, four groups were prepared as below:

- The group without transplantation as a control (A),
- The group that underwent amniotic cell transplantation only (B),
- The limbic cell transplant group only (C),
- The group with the combined transplant (amniotic cell÷ limbic cell) (D),

All rabbits were kept on an empty stomach for four hours. The sedation was performed with Midazolam (0.5 mg/kg intramuscularly), and anesthesia with Propofol (5 mg/kg intravenously) injected slowly to avoid the risk of apnea<sup>9</sup>.



**Figure 2: Corneal opacity.**

An eyelid retractor was placed, and the biopsy was performed in the limbic region of the left eye over an arc of about 70°C to 80°C, 1 mm deep and 2 mm towards the cornea (Figure 1). A cotton swab immersed

in 4% hydrogen chloride was applied, at the center of the cornea for 2 seconds, and washed immediately with a saline solution to limit diffusion of caustic to the rest of the ocular surface (Figure 2). Each biopsy was transported in a sterile vial containing a culture medium (DMEM), after that transferred to an identified Nunc dish for the observation by electronic microscopic (Figure 3: a), then to a conical tube containing 1ml of trypsin solution at 0.25%. After 5 minutes of contact, each tube was washed with 3 ml of PBS to inhibit the enzymatic action. All tubes were centrifuged at 500 G for 5 minutes, and incubated the recovered pellets in identified Petri dishes at 5% CO<sub>2</sub> and 37°C<sup>8</sup>. Amniotic membranes were extracted from a pregnant rabbit and transported in a sterile vial containing culture medium (DMEM). A microscopic examination was performed by emptying the vial into an identified Nunc box (Figure 3b). The contents were transferred to a large Petri dish for cutting and cleaning from the conjunctive tissue. Washing was performed in a conical tube containing a PBS solution. The tube was centrifuged twice in PBS to clean cells at 500 G for 5 minutes, and the pellet was cultivated in a petri dish under the same conditions as mentioned above<sup>9</sup>. The culture medium used contains a base of DMEM/F12 with fetal calf serum 10 %, glutamine 2mM, non-essential amino acids 0.1M and antibiotic (penicillin 10,000 u/ml, streptomycin 10,000 µg/ml) and antifungal agent 0.1 % Nystatin<sup>10</sup>. During the proliferation process, the culture medium was changed every two days and performed trypsinization and passage at the level of 70% cell confluence. The proliferation was stopped after two passages. the proliferated stem cells were filled into two tubes per individual, each containing a volume of 500 ml (10<sup>6</sup> cells/ml), the first tube intended for transplantation and the second tube intended for cryopreservation, in which an equal volume of a freezing solution (80% DMSO + 20% FBS) was added. The tubes were left at - 80°C for one night before transferring them into liquid nitrogen<sup>12</sup>. The rabbit candidates were kept for transplantation on a fast stomach for four hours before the anesthesia. After applying the eyelid retractor, a small incision was made in the cornea through which passed a curved knife to separate the damaged epithelium from the stroma. Under this epithelium, the cell content was introduced for grafting using a syringe equipped with a fine, flexible catheter. The four test groups were treated with local treatment (antibiotic and anti-inflammatory) for 15 days, and the postoperative monitoring was extended for up to 2 months.




Figure 3: a-b . a microscopic examination for limbal and amniotic biopsy.

## RESULTS

Microscopic examination of the samples showed that the amniotic membranes were in perfect condition and that limbal cells were present in all biopsies. The caustic induced an immediate opacity of the cornea, visible with Trypan blue (Figure 2). The rabbits showed very good clinical performance after biopsies and transplantation, with no postoperative complications, no signs of infection, no neovascularization of the cornea, and no graft rejection.

In only 10 days, rabbits that received amniotic stem cells alone developed temporary anatomical improvement without functional recovery (Group B). Rabbits that received a combined graft of limbal and amniotic stem cells showed a clear anatomical and functional improvement compared to those that received limbal stem cells alone (Group D), but both regained their visual abilities. The control group (rabbit without grafting) showed unilateral blindness without anatomical improvement during the two months of follow-up (Group A) (Figure 4).

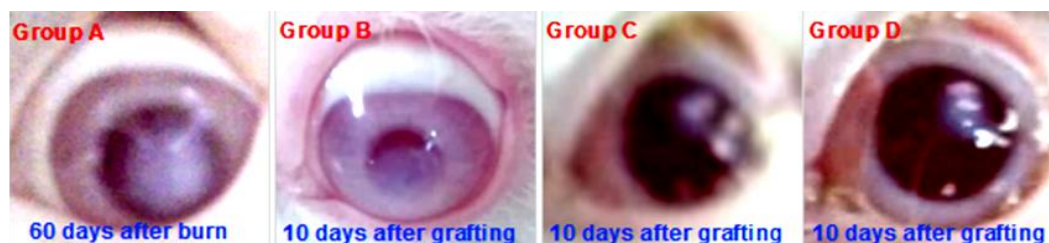

Figure 4: Anatomical evolution of the ocular surface for the four study groups.

## DISCUSSION

All groups tested developed a corneal ulcer (Figure 2). Without stem cell transplantation, the ulcer was complicated by a severe limbal deficit and unilateral blindness (Group A)<sup>5</sup>. There was a temporary anatomical improvement, but no improvement in visual acuity for the group that received an amniotic cell transplant (Group B). The anatomical and functional recovery observed for groups C (limbal stem cells) and D (mixed limbal and amniotic stem cells) was so rapid and significant for group D. Various cellular and molecular processes started; first, the caustic agent destroys the epithelial cell membranes around the cornea and limbus and the extracellular matrix composed of structural proteins (collagen, laminin, and fibronectin) and signaling proteins (integrin and metalloproteinase)<sup>6,7,8</sup>. Two systems are activated, the metalloproteinases that break down proteins in the extracellular matrix and the system that converts plasminogen to plasmin. Plasmin intervenes in the cleavage of extracellular matrix proteins and activates the TGF- $\beta$  pathway and pro-collagenases<sup>6,7,8-10</sup>. This hyperactivity leads to the fusion of the stroma<sup>21</sup>. Secretions from the limbal blood vessels, the tear film, or the aqueous humor, inhibit the expansion of the lesion into the underlying tissues<sup>1,2</sup>. Underlying cells that escape caustic action modify their cytoskeleton

and increase their metabolism to produce the various proteins of the cytoskeleton (vinculin, actin, talin, and integrin)<sup>22,23</sup>. Fibronectin, fibrinogen, and fibrin reach the site of damage by limbal blood vessels and participate in the reconstitution of a temporary extracellular matrix consisting of tenascin, lumican, and laminin, which facilitates the migration of epithelial cells<sup>24,25</sup>. Laminin reduces gene expression in integrin subunits by altering the level of sp1 and sp3 transcription factors, which reduces integrin production and facilitates the detachment of intact epithelial cells from the basement membrane. These cells modify their differentiation and proliferation properties to regenerate a neo-epithelium<sup>26,27</sup>. This process is known as vertical renewal and requires continuous multiplication and migration of stem cells from the limbus to satisfy the need, which becomes impossible if the niche is damaged. The amniotic cells contain epithelial stem cells (ESC) and stromal or mesenchymal stem cells (SSC, MSC)<sup>28</sup>, while the limbal cells contain epithelial stem cells (ESC) and mesenchymal stem cells (MSC)<sup>3,29,30</sup>. After transplantation, only the epithelial cells migrate to the recently synthesized fibronectin matrix<sup>31,32</sup>, and consist the intercellular and matrix contacts as a protective barrier<sup>10,11,20,21,33</sup>. Reassembly of the hemidesmosomes at the basal pole of the limbal epithelial cells facilitates their adhesion to the basement membrane to form a temporary corneal epithelium<sup>21,33</sup>. The limbal graft cell



joins the limbus and divides asymmetrically into a small cell that remains in the niche (pool renewal) and a large differentiated cell called the transient amplifier cell (TAC). This TAC proliferates and migrates from the limbus to the centre of the cornea<sup>4,11,13</sup>. This explains the permanent renewal provided by limbal stem cell transplantation. Studies on laboratory animals describe the beneficial effect of MSCs on corneal healing after the application of their conditioned medium or after their implantation in injured tissue<sup>5,9</sup>. These cells produce growth factors (KGF; HGF; EGF; TGF and bFGF) and cytokines that facilitate corneal reepithelialization<sup>20,31,34,35</sup>, prevent apoptosis of epithelial cells<sup>24,36-38</sup>, promote their differentiation and migration<sup>12,39</sup>, and enhance their adhesion<sup>11,40</sup>. They also have anti-adhesive, antibacterial, and antifungal properties that inhibit microbial colonization<sup>37</sup>; and anti-angiogenic properties that reduce neo-vascularization and the invasion of conjunctival tissue (Ptérygion)<sup>8,24,37,38</sup>. Amniotic epithelial cells produce anti-inflammatory cytokines such as IL-1Ra and IL-10 that block the inflammatory cascade and inhibit metalloproteinases<sup>36-39</sup>. Finally, these cells have the advantage of not expressing histocompatibility antigens and therefore do not cause a rejection reaction<sup>38</sup>. Amniotic epithelial and mesenchymal cells can synthesize thrombospondin-1, endostatin, and metalloproteinase tissue inhibitors (TIMPs)<sup>15-18,39</sup>. Simultaneous amniotic cell transplantation has shown that it can be an important complement to auto or limbal allograft techniques<sup>31,32,40</sup>. It was discovered that a temporary therapeutic result with the amniotic stem cell transplantation compared to a synergistic, rapid and permanent result obtained with the combined amniotic and limbal stem cell transplant, thanks to the supportive effect of amniotic stem cells and the regenerative effect of limbal stem cells. This therapeutic alternative has successfully repaired the caustic corneal burn and restored the limbic deficit. In humans, it will replace and surpass the various therapies used in this sense, as it is technically fast, inexpensive, and with a short time of recovery.

## ACKNOWLEDGMENTS

The authors wish to thank all the people who participated directly or indirectly in the realization of this work, more precisely the team of Professor "Azeddine IBRAHIMI." and the team of Professor "Gamal TAOUFIK.", as well as the other teams from the different departments of the Faculty of Medicine and Pharmacy of Rabat.

## AUTHOR'S CONTRIBUTION

**Salama A:** writing original draft, methodology. **Abudunia AM:** investigation, conceptualization. **Al-kaf AG:** formal analysis, interpretation of data. **Ziad NM:** editing, methodology. **Ibrahimi A:** investigation, supervision. **Chabraoui L:** data curation, conceptualization. All authors revised the article and approved the final version.

## DATA AVAILABILITY

The datasets generated during this study are available from the corresponding author upon reasonable request.

## CONFLICT OF INTEREST

No conflict of interest associated with this work.

## REFERENCES

1. Tsubota K, Tseng SCG, Nordlund ML. Anatomy and Physiology of the Ocular Surface. Ocular Surface Disease Medical and Surgical Management. Springer, New York, NY, 2002:3–15.
2. Knop E, Knop N. Anatomy and Immunology of the Ocular Surface. Immune Response and the Eye. Chem Immunol Allergy. Basel, Karger 2007; 92:36–49. <https://doi.org/10.1159/000099252>
3. Copeland RA, Afshari N. Copeland and Afshari's Principles and Practice of Cornea. 2013.
4. Shukla IM. Amniotic membrane grafts in corneal ulcer. Indian J Ophthalmol 1962; 10(3):55–60.
5. Kim JC, Tseng SC. The effects on inhibition of corneal neovascularization after human amniotic membrane transplantation in severely damaged rabbit corneas. Korean J Ophthalmol 1995; 9(1):32–46. <https://doi.org/10.3341/kjo.1995.9.1.32>
6. Khodadoust AA, Silverstein AM, Kenyon KR, Dowling JE. Adhesion of regenerating corneal epithelium: the role of basement membrane. American J Ophthalmol 1968; 65(3):339–348. [https://doi.org/10.1016/0002-9394\(68\)93082-1](https://doi.org/10.1016/0002-9394(68)93082-1)
7. Davanger M, Evensen A. Role of the pericorneal peripapillary structure in renewal of corneal epithelium. Nature 1971; 229(5286):560–561. <https://doi.org/10.1038/229560a0>
8. Gris O, Plazas A, Lerma E, et al. Conjunctival resection with and without amniotic membrane graft for the treatment of superior limbic keratoconjunctivitis. Cornea 2010; 29(9):1025–1030. <https://doi.org/10.1097/ICO.0b013e3181d1d1cc>
9. Buck RC. Cell migration in repair of mouse corneal epithelium. Invest Ophthalmol Visual Sci 1979; 18:767–784. PMID: 457355
10. Kruse FE. Stem-cells and corneal epithelial regeneration. Eye. 1994; 8(2):170–183. <https://doi.org/10.1038/eye.1994.42>
11. López García JS, Jara RL, García Lozano I, Murube J. Histopathologic limbus evolution after alkaline burns. Cornea 2007; 26(9):1043–1048. <https://doi.org/10.1097/ICO.0b013e31812375fd>
12. Visse R, Nagase H. Matrix metalloproteinases and tissue inhibitors of metalloproteinases: structure, function, and biochemistry. Circ Res 2003; 92(8):827–839. <https://doi.org/10.1161/01.RES.0000070112.80711.3D>
13. Yu Q, Stamenkovic I. Cell surface-localized matrix metalloproteinase-9 proteolytically activates TGF-beta and promotes tumor invasion and angiogenesis. Genes Dev 2000; 14(2):163–176. PMID: 10652271
14. Fini ME, Cook JR, Mohan R. Proteolytic mechanisms in corneal ulceration and repair. Archives Dermatol Res 1998; 290(1):S12–S23. <https://doi.org/10.1007/pl00007449>
15. Zieske J, Hutcheon AE, Guo X, Chung EH, Joyce NC. TGF-beta receptor types I and II are differentially expressed during corneal epithelial wound repair. Invest Ophthalmol Visual Sci 2001; 42(7):1465–1471. PMID: 11381048
16. Ye HQ, Maeda M, Yu FS, Azar DT. Differential expression of MT1-MMP (MMP-14) and collagenase III

- (MMP-13) genes in normal and wounded rat corneas. *Invest Ophthalmol Visual Sci* 2000;41(10):2894–2899. PMID: 10967042
17. Wilson SE, Mohan Rahul R, Mohan Rajiv R, et al. The corneal wound healing response: cytokine-mediated interaction of the epithelium, stroma, and inflammatory cells. *Progress Ret Eye Res* 2001; 20(5):625–637. [https://doi.org/10.1016/s1350-9462\(01\)00008-8](https://doi.org/10.1016/s1350-9462(01)00008-8)
  18. Yoon J, Ismail S, Sherwin T. Limbal stem cells: Central concepts of corneal epithelial homeostasis. *World J Stem Cells* 2014; 6(4):391–403. <https://doi.org/10.4252/wjssc.v6.i4.391>
  19. Zieske JD, Gipson IK. Protein synthesis during corneal epithelial wound healing. *Invest Ophthalmol Visual Sci* 1986; 27(1):1–7.
  20. Agrawal VB, Tsai RJ. Corneal epithelial wound healing. *Indian J Ophthalmol* 2003; 51(1):5–15.
  21. Zieske JD. Extracellular matrix and wound healing. *Curr Opin Ophthalmol* 2001; 12(4):237–241. <https://doi.org/10.1097/00055735-200108000-00001>
  22. Gaudreault M, Carrier P, Larouche K, et al. Influence of sp1/sp3 expression on corneal epithelial cells proliferation and differentiation properties in reconstructed tissues. *Investigative Ophthalmol Visual Sci* 2003; 44(4):1447–1457. <https://doi.org/10.1167/iovs.02-0707>
  23. Gaudreault M, Vigneault F, Leclerc S, Guerin SL. Laminin reduces expression of the human alpha6 integrin subunit gene by altering the level of the transcription factors Sp1 and Sp3. *Invest Ophthalmol Visual Science* 2007;48(8):3490–3505. <https://doi.org/10.1167/iovs.07-0016>
  24. Roubelakis MG, Bitsika V, Zagoura D, et al. *In vitro* and *in vivo* properties of distinct populations of amniotic fluid mesenchymal progenitor cells. *J Cell Mol Med* 2011; 15(9):1896–1913. <https://doi.org/10.1111/j.1582-4934.2010.01180.x>
  25. Reinshagen H, Auw-Haedrich C, Sorg RV, et al. Corneal surface reconstruction using adult mesenchymal stem cells in experimental limbal stem cell deficiency in rabbits. *Acta Ophthalmol* 2011; 89(8):741–748. <https://doi.org/10.1111/j.1755-3768.2009.01812.x>
  26. Choong PF, Mok PL, Cheong SK, et al. Mesenchymal stromal cell-like characteristics of corneal keratocytes. *Cytotherap* 2007; 9(3):252–258. <https://doi.org/10.1080/14653240701218508>
  27. Koizumi N, Inatomi T, Quantock AJ, et al. Amniotic membrane as a substrate for cultivating limbal corneal epithelial cells for autologous transplantation in rabbits. *Cornea* 2000; 19(1):65–71. <https://doi.org/10.1097/00003226-200001000-00013>
  28. Avila M, España M, Moreno C, Peña C. Reconstruction of ocular surface with heterologous limbal epithelium and amniotic membrane in a rabbit model. *Cornea* 2001; 20(4):414–420. <https://doi.org/10.1097/00003226-200105000-00016>
  29. Suzuki K, Saito J, Yanai R, et al. Cell-matrix and cell-cell interactions during corneal epithelial wound healing. *Prog Retin Eye Res* 2003; 22(2):113–133. [https://doi.org/10.1016/S1350-9462\(02\)00042-3](https://doi.org/10.1016/S1350-9462(02)00042-3)
  30. Yu FS, Yin J, Xu K, Huang J. Growth factors and corneal epithelial wound healing. *Brain Res Bull* 2010;81(2-3):229–235. <https://doi.org/10.1016/j.brainresbull.2009.08.024>
  31. Koizumi NJ, Inatomi TJ, Sotozono CJ, et al. Growth factor mRNA and protein in preserved human amniotic membrane. *Curr Eye Res* 2000; 20(3):173–177. PMID: 10694891
  32. Shimmura S, Shimazaki J, Ohashi Y, Tsubota K. Anti-inflammatory effects of amniotic membrane transplantation in ocular surface disorders. *Cornea* 2001; 20(4):408–413. <https://doi.org/10.1097/00003226-200105000-00015>
  33. Hori J, Wang M, Kamiya K, Takahashi H, Sakuragawa N. Immunological characteristics of amniotic epithelium. *Cornea* 2006; 25:S53–S58. <https://doi.org/10.1097/01.ico.0000247214.31757.5c>
  34. Li H, Niederkorn JY, Neelam S, et al. Immunosuppressive factors secreted by human amniotic epithelial cells. *Invest Ophthalmol Visual Sci* 2005; 46(3):900–907. <https://doi.org/10.1167/iovs.04-0495>
  35. Hanna C. Proliferation and migration of epithelial cells during corneal wound repair in the rabbit and the rat. *Am J Ophthalmol* 1966; 61(1):55–63. PMID: 5904378
  36. Tseng SC, Espana EM, Kawakita T, et al. How does amniotic membrane work? *Ocular Surf* 2004;2(3):177–187. [https://doi.org/10.1016/s1542-0124\(12\)70059-9](https://doi.org/10.1016/s1542-0124(12)70059-9)
  37. Hao Y, Ma DH, Hwang DG, Kim WS, Zhang F. Identification of anti-angiogenic and anti-inflammatory proteins in human amniotic membrane. *Cornea* 2000; 19(3):348–352. <https://doi.org/10.1097/00003226-200005000-00018>
  38. Kenyon KR. Limbal autograft transplantation for chemical and thermal burns. *New Microsurgical Concepts II*. 1989; 18, 53-58.
  39. Kim JS, Kim JC, Na BK, Jeong JM, Song CY. Amniotic membrane patching promotes healing and inhibits proteinase activity on wound healing following acute corneal alkali burn. *Exp Eye Res* 2000; 70(3):329–337. <https://doi.org/10.1006/exer.1999.0794>
  40. Bauman WR, Cosby DC, Fulks J, Lammert MJ. *Microbiology with diseases by body system*. 4<sup>th</sup> ed. 2009 Pearson Education, New York, US. 2019; 582-583.
  41. Mounerou S, Maléwé K, Anoumou DY, Sami N, Koffi A, Mireille P. Seroprevalence of rubella IgG antibody among pregnant women attending antenatal clinic in Lomé, Togo. *Am J Infect Dis Microbiol* 2015; 3(4):134–136. <https://doi.org/10.12691/ajidm-3-4-3>