



RESEARCH ARTICLE

EVALUATION OF SUB-ACUTE TOXICITY OF THE HYDRO-METHANOL STEM BARK EXTRACT OF *BURKEA AFRICANA* IN ALBINO RATS

Terhemem Festus Swem^{*1}, Patrick Emeka Aba², Samuel Chukwunke Udem²,

Victor Masekaven Ahur¹, Fidelis Aondover Gberindyer³

¹Department of Veterinary Physiology and Biochemistry, College of Veterinary Medicine, Federal University of Agriculture, Makurdi, Benue State, Nigeria.

²Department of Veterinary Physiology and Pharmacology, Faculty of Veterinary Medicine, University of Nigeria, Nsukka, Enugu State, Nigeria.

³Department of Veterinary Pharmacology and Toxicology, College of Veterinary Medicine, Federal University of Agriculture, Makurdi, Benue State, Nigeria.

Article Info:



Article History:

Received: 12 December 2020

Reviewed: 13 January 2021

Accepted: 18 February 2021

Published: 15 March 2021

Cite this article:

Swem TF, Aba PE, Udem SC, Ahur VM, Gberindyer FA. Evaluation of sub-acute toxicity of the hydro-methanol stem bark extract of *Burkea africana* in albino rats. Universal Journal of Pharmaceutical Research 2021; 6(1):16-24. <https://doi.org/10.22270/ujpr.v6i1.534>

*Address for Correspondence:

Dr. Terhemem Festus Swem, Department of Veterinary Physiology and Biochemistry, College of Veterinary Medicine, Federal University of Agriculture, Makurdi, Benue State, Nigeria. Tel- +2348165743539; E-mail: swemfestus422@gmail.com

Abstract

Objective: This study was designed to investigate the sub-acute toxicity profile of hydro-methanol extract of *B. africana* (BA) stem bark in rats.

Methods: The stem bark of BA was extracted by cold maceration using 80% methanol. Twenty female albino rats were randomly assigned into four groups of five rats each. Group 1 (only distilled water). Groups 2-4 received the extract (100, 200, and 400 mg/kg) orally, once daily for 28 days. The rats were observed for signs of toxicity and the bodyweight (b.wt) of rats taken weekly. Blood samples were collected on day 28 for hematology and serum chemistry. Visceral organs were harvested for organ-somatic index and histopathology.

Results: There were no toxicity signs observed and no significant ($p < 0.05$) change in body weight but the pulmo-somatic index was significantly ($p < 0.05$) higher at 400 mg/kg compared with the control and other treated groups. Significant ($p < 0.05$) increase in PCV, RBC, and MCV and significant ($p < 0.05$) decrease in MCHC, Total WBC count, neutrophils and lymphocytes were observed. Also, there were significant ($p < 0.05$) decreases in ALT, total protein, globulin, total bilirubin of test groups when compared with the control group. Urea concentration of test groups significantly ($p < 0.05$) increased when compared with that of the control group.

Conclusions: BA stem bark extract can be said to have no deleterious effect on erythrocyte, but rather serve to improve erythropoiesis and also has no overt toxic effect on the visceral organs. Also the extract may have immunosuppressive and oxidative tendencies on prolong use.

Keywords: Biochemical changes, gas chromatography, immunosuppression, medicinal plants, mass spectrometry, oxidative stress.

INTRODUCTION

The act of using plants for treatment, prevention, and control of various disease conditions is an ancient phenomenon^{1,2}. Developed countries also have experienced significant increase in the use of herbal remedies, with the belief that they are more efficacious and less harmful^{2,3}. Nonetheless, the fact that they are natural does not make them safe, because little knowledge is available on the safety to validate the claim by manufacturers or traditional healers^{2,3}. Many herbal products or medicinal plants have been demonstrated by researchers to be toxic, mutagenic,

and carcinogenic⁴. Research has also shown that many medical plants used as herbal remedies contain phytochemical constituents with ability to cause deleterious effect to the body. Such toxic principles include pyrrolizidine alkaloids, benzophenanthrine alkaloids, lectins, saponins, diterpenes, cyanogenic-glycosides, and furanocoumarins². Evaluation of medicinal plant and herbal products to determine the level of toxicity in order to establish consequences of long term use is therefore imperative. Toxicity may be seen physically and clinically. Animals or humans may display signs such as restlessness, ataxia, circling, anorexia and subsequently death. The effect of the

toxic agent is often seen on the organs especially the liver, kidney, lungs, and heart. This often displays as changes in some biochemical parameters which gives a picture of which organ is mostly affected.

B. africana (Caesalpinaceae), a medium size deciduous tree with a wide spread top common in Nigeria is widely used as a remedy for a wide range of ailments in traditional medicine. It has been used often as an anti-venomous agent, cutaneous and subcutaneous parasitic infections, anticonvulsant, hepatic disorders, analgesic, anti-inflammation, anti-diarrheal, wound healing, and toothache⁵⁻⁷. Empirical evidences exist on its antibacterial, anti-fungal, larvicidal, molluscicidal, and antioxidant activities⁸⁻¹⁰. Also, claims for its anti-diarrheal, anticonvulsant, analgesic, and anti-inflammatory properties have been reported^{7,11,12}. In this study, the GC-MS analysis and the sub-acute toxicity of methanol stem bark extract of BA were investigated.

MATERIALS AND METHODS

Plant material

Fresh stem bark of *B. africana* (BA) were obtained from Ajaba village, a sub-urb of Makurdi metropolis in Benue State and identified by Plant Taxonomists Mr. Yeke Titus of the Department of Forestry, Federal University of Agriculture Makurdi and a voucher specimen number; UAM/FH/0326 assigned and kept in the Departmental Herbarium.

Preparation of plant extract

The BA stem bark was dried in an open shade at room temperature and pounded into smaller piece using a mortar and pestle. This was further made into powdered form using a grinding machine. The powdered material (1000 g) was soaked in 4 L of 80% methanol for 48 h with periodic shaking. The extract was then filtered with a Whatman (No. 1) filter paper. The filtrate was concentrated in a vacuum using a hot air oven at 37°C into a semi-solid form, yielding in a ratio of 1:10 w/v crude to extract and stored at 4°C in the refrigerator for future use.

Experimental animals

Female rats weighing 110-120 g were purchased from a commercial animal farm in Nsukka, Enugu State. The animals were kept for seven days in Aluminum cages to acclimatize at the animal house of the Department of Veterinary Physiology and Pharmacology, Faculty of Veterinary Medicine, University of Nigeria Nsukka. During this period, they were provided with potable drinking water and fed adequately with commercially prepared poultry feed pellets (Topfeeds®). The Ethical Committee of the Department of Veterinary Physiology and Pharmacology, University of Nigeria Nsukka gave approval for this research to be conducted with the approval reference number: FVM-VPP-UNN-IACUC-2018-039. The handling and management of animals during this period was in line with good laboratory animal practice regulations as well as the principles of laboratory animal use and care as enshrined by the Natural Research Council guidelines of 2011¹³.

Phytochemical Screening of extracts

The phytochemical screening of the 80% methanol extract of BA stem bark was carried out using standard procedures as described by Trease and Evans¹⁴ and Sofowora^{16,17}. The powdered hydro-methanol extract of BA stem bark was reconstituted to obtain the test aliquot by dissolving 1 g in 500 ml of distilled water. The aliquot was thereafter screened for the presence of alkaloids, flavonoids, tannins, phlebotannins, saponins, glycosides, phenols, terpenoids, steroids, reducing sugar, resins, and volatile oils.

Gas chromatography mass spectroscopy

One gram (1g) of the methanol stem bark extract of BA was sent to Ahmadu Bello University, Zaria for Gas Chromatography Mass Spectroscopy (GC-MS) analysis (Perkin Elmer Auto sampler XLGC coupled with Turbo Mass Spectrophotometer, Norwalk CTO6859, USA) using analytical conditions described by Adeyemi *et al.*,¹⁷. The setup had an electron ionization of 70v and the source of the ion had a temperature of 250°C. Helium gas (99.9% purity) was the carrier gas used, while HP-5ms (30mm X 0.25mm X 0.320 µm) was the stationary phase. The oven had a temperature of 80°C and was kept at that for 5 minutes and then increased to 250°C. The retention time was 16 minutes, running at the speed of 4 degrees/minute, 1µl was automatically injected to finalize the running time of 50 minutes. Mass Hunter Data Analysis Software was used to analyze and interpret the GC-MS result.

Sub-acute toxicity experiment

Twenty female albino rats randomly were assigned into four groups. Groups 2-4 were administered the extract at the dose of 100, 200, and 400 mg/kg b.wt respectively, orally for 28 consecutive days. Whereas group 1 served as a negative control and were administered distilled water at 10 ml/kg body weight for the period. The body weights of rats in each group were obtained weekly and recorded accordingly. Blood samples for hematology and serum biochemistry were collected at day 28 post treatments using standard methods. All rats in each group were sacrificed humanely at day 28 and visceral organs (liver, kidney, heart, spleen and lung) were collected, weighed and relative organ versus body weight calculated. Liver and kidneys were preserved using 10% formalin to be used for histopathology examination.

Hematological and serum biochemical analyses

Hematological parameters were evaluated using standard methods¹⁸. Also, alanine amino transferase (ALT), aspartate amino transferase (AST) and alkaline phosphatase (ALP) were assayed as described^{19,20}. Total serum protein and albumin were evaluated using a clinical refractometer as described by Johnson *et al.*,²¹. Serum globulin concentrations were derived from the difference between total serum protein and albumin. Total and direct bilirubin assay was by the method of Tietz²² while Urea and creatinine were assayed by the method of Burtis and Ashwood²³. Also, malondialdehyde, catalase and glutathione were assayed by the methods of Stocks and Dormandy²⁴ modified by Sicinska *et al.*,²⁵, Góth²⁶, and Moron *et al.*,²⁷.

Histopathological Examination

Tissue samples from the liver and kidney were histologically examined using the conventional staining technique of Hematoxylin and Eosin as described by Drury et al.,²⁸.

Statistical analysis

All results of this study were expressed descriptively as mean±standard error of mean (S.E.M) and group

means were compared using one-way analysis of variance (ANOVA) at significance level of 5% ($p < 0.05$). Significant differences between means were separated using Duncan multiple range post hoc test. Data was analyzed using SPSS version 21. Bar charts and tables were used to present the data generated in the study.

Table 1: GC-MS profile of methanol extract of *B. africana* stem bark.

S.N.	Suggested compound	Molecular Formula	Molecular weight (g/mol)	Retention Time (Min.)	Chemical Group
1	(2H) pyrrole-2-carbonitrile, 5-amino-3,4-dihydro-	C ₅ H ₇ N ₃	109	15.712	Alkaloid
2	1-Butanamine, N-nitroso-N-propyl	C ₇ H ₁₆ N ₂ O	144	18.386	Amine
3	Resorcinol	C ₆ H ₆ O ₂	110	28.424	Phenol
4	Oleic acid	C ₁₈ H ₃₂ O ₂	282	55.937	Fatty acid
5	9, 17-octadecadienal, (Z)-	C ₁₈ H ₃₂ O	265	60.553	Unsaturated Aldehyde

RESULTS

Phytochemical screening

Qualitative phytochemical screening of the extract showed that the extract contained alkaloids, glycosides, resins, reducing sugars, volatile oil and phlobotannins, flavonoids, saponins, sterols, terpenes tannins, terpenoids, and phenols.

Gas chromatography mass spectroscopy of methanol extract of *B. africana* stem bark

Results of the GC- MS analysis of the plant extract are presented in Table 1. Results suggested that the extract contains (2H) pyrrole-2-carbonitrile, 5-amino-3,4-dihydro-,1-Butanamine,N-nitroso-N-propyl, Resorcinol, Methyl 11-oxo-9-undecenate, Oleic acid, and 9, 17-octadecadienal, (Z).

Sub-acute effects of the extract on organ-somatic index and body weight

Results showed no significant different in the organ-somatic index between the control and treated groups for all the organs. However, the pulmo-somatic index was higher in animals treated at the dose rate of 400 mg/kg of the extract as compared with the control and other treated groups (Figure 1). Also, No significant ($p > 0.05$) difference was observed in the body weights of animals in all the treated groups when compared with the control group (Figure 2).

Effects on some hematological parameters

Result in Table 2 showed significantly ($p < 0.05$) higher values of packed cell volume (PCV) and red blood cells (RBC) in animals treated with the extract at the dose rate of 200 mg/kg and 400 mg/kg as compared to those administered 100 mg/kg dose of the extract as well as the control group.

No significant ($p > 0.05$) difference in the hemoglobin (Hb) and mean corpuscular hemoglobin (MCH) values between all the treated and the control groups.

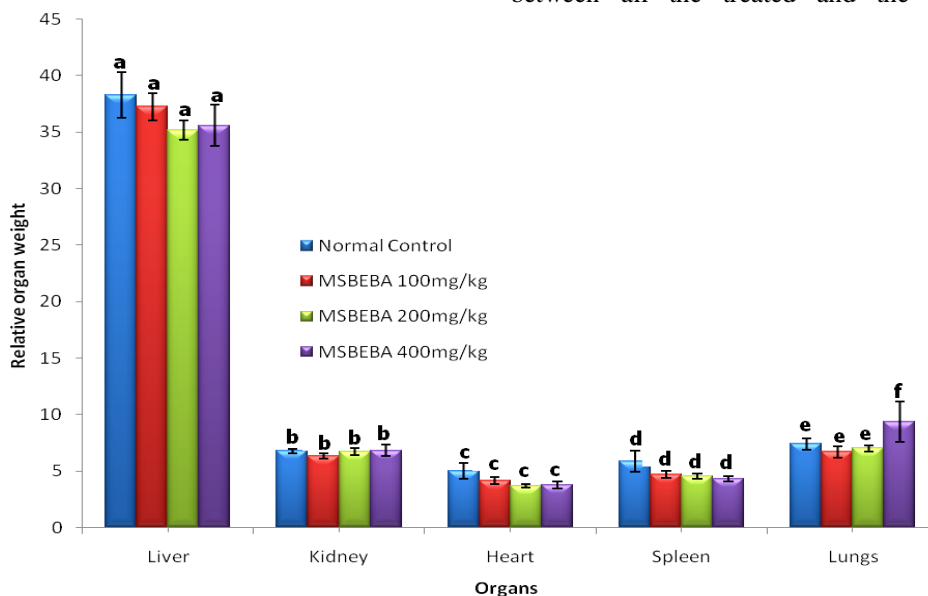


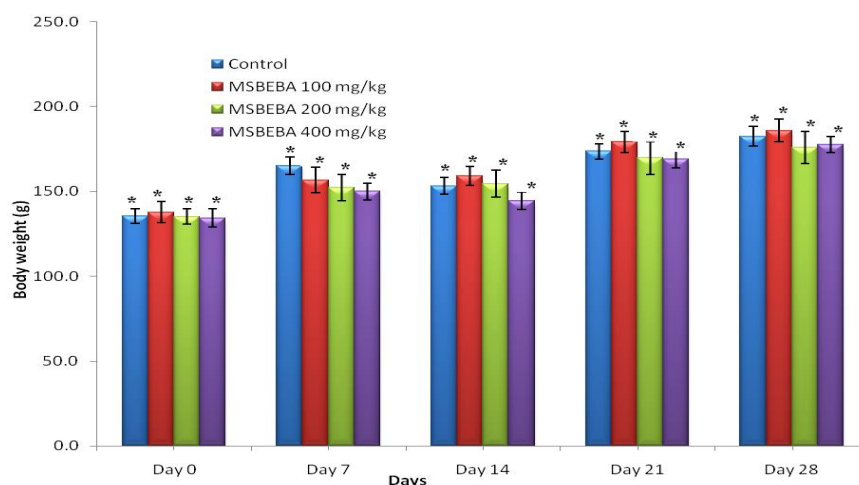
Figure 1: Organ-somatic index of rats treated for 28 days with methanol extract of *B. africana* stem bark (x10³g).

Bars with the same alphabet for each organ (liver, kidney, heart, spleen and lungs) are not significantly ($p < 0.05$) different for each. MSBEBA- Methanol stem bark extract of *B. africana*.

Table 2: Haematological parameters of rats treated with methanol extract of *B. africana* stem bark for 28 days.

Parameters	Control	Extract Treated Groups		
		100 mg/kg	200 mg/kg	400 mg/kg
PCV (%)	42.00±1.18 ^a	44.60±2.20 ^{ab}	51.67±0.76 ^c	48.20±1.69 ^{bc}
Hb (g/dL)	15.00±0.27 ^a	15.75±0.26 ^a	15.52±0.33 ^a	15.28±0.46 ^a
RBC (X10 ¹² /L)	7.48±0.03 ^a	7.55±0.02 ^a	7.64±0.03 ^b	7.72±0.04 ^b
MCV (fL)	56.11±1.45 ^a	68.43±0.91 ^c	58.39±2.92 ^{ab}	62.40±1.92 ^b
MCH (Pg)	20.04±0.30 ^a	20.87±0.37 ^a	20.32±0.45 ^a	19.79±0.60 ^a
MCHC (g/dL)	35.79±0.72 ^b	30.55±0.89 ^a	35.02±1.22 ^{bc}	31.87±1.58 ^{ab}
TWBC (X/10 ¹² /L)	6.77±1.89 ^b	6.60±0.19 ^b	5.84±0.07 ^a	5.48±0.10 ^a
Neutrophils (%)	65.67±1.87 ^b	61.67±1.20 ^a	68.00±0.89 ^b	69.60±0.40 ^b
Lymphocytes (%)	31.67±2.09 ^b	36.00±1.46 ^b	32.40±2.48 ^b	26.00±1.26 ^a
Monocytes	2.33±0.33 ^a	1.67±0.61 ^a	2.00±0.63 ^a	3.20±0.49 ^a
Eosinophils (%)	0.00±0.00 ^a	1.00±0.45 ^a	0.40±0.40 ^a	0.80±0.49 ^a
Basophils	0.33±0.33 ^a	0.00±0.00 ^a	0.00±0.00 ^a	0.40±0.40 ^a

Values are Mean±S.E.M, n = 5. Values with different superscripts on the same row are significantly different at $P < 0.05$. PCV-Packed cell volume, Hb-Hemoglobin, RBC-Red blood cell count, MCV-Mean corpuscular volume, MCH-Mean corpuscular hemoglobin, MCHC-Mean corpuscular hemoglobin concentration, and TWBC-Total white blood cell.

**Figure 2: Weekly Mean body weight of rat treated with methanol extract of *B. africana* stem bark in grams (g)±SEM**

Bars with asterisks for various days are not significantly ($p < 0.05$) MSBEBA-Methanol stem bark extract of *B. africana*.

Also, the mean corpuscular volumes (MCV) were observed to be significantly ($p < 0.05$) higher in animals administered the extract at doses 100 mg/kg and 400 mg/kg compared to the control and the group treated at the dose of 200 mg/kg. Only animals treated with the extract at the dose rate of 100 mg/kg were observed with a significantly ($p < 0.05$) lower MCHC value as compared to both the other two treated and the control groups. Furthermore, result revealed a significantly ($p < 0.05$) higher total white blood count (TWBC) in those animals treated with 200 and 400 mg/kg dose of the extract as compared with the control group as well as those given a 100 mg/kg dose of the extract. For the neutrophils count, a significantly ($p < 0.05$) lower value was observed in the animals that were treated with the extract at a dose rate of 100 mg/kg when compared with the control and those treated with the higher doses. Again, a significantly ($p < 0.05$) lower lymphocyte count was observed in those animals that were treated with the extract at a dose rate of 400 mg/kg when compared to the control group and the other two groups on lower doses. Furthermore, the result showed no significant ($p > 0.05$) difference between the extract treated and control groups in the

observed values of monocytes, eosinophil, and basophils.

Effect on some serum biochemical parameters

In Table 3 results of biochemical assay showed significantly ($p < 0.05$) decreased in rats treated with the extract at the dose rate of 100 and 200 mg/kg when compared with those treated at the dose rate of 400 mg/kg and the control group. Total proteins were significantly ($p < 0.05$) lower at all the doses of extract administered, when compared with the control group. Albumin showed significantly ($p < 0.05$) higher values in animals treated with the extract at the dose rate of 100 and 200 mg/kg when compared with the group administered 400 mg/kg of the extract and the control group. Globulin decreased significantly ($p < 0.05$) in animals treated with the extract at the dose rate of 100, 200 and 400 mg/kg. Also total bilirubin was significantly ($p < 0.05$) lowered in animals administered 100 mg/kg of the extract when compared with those administered 200 and 400 mg/kg and control group. Urea significantly ($p < 0.05$) increased in animals treated with the extract at the dose rate of 200 and 400 mg/kg when compared with those administered the extract at the dose rate of 100 mg/kg and control group.

Table 3: Some serum biochemical parameters of rats treated with methanol extract of *B. africana* stem bark for 28 days.

Groups	Control	Extract Treated Groups		
		100 mg/kg	200 mg/kg	400 mg/kg
AST (IU/L)	61.67±2.64 ^a	58.50±3.43 ^a	56.60±3.30 ^a	62.00±2.70 ^a
ALT (IU/L)	38.57±1.70 ^b	34.18±0.58 ^a	33.28±0.88 ^a	35.51±1.15 ^{ab}
ALP (IU/L)	94.77±1.31 ^a	96.18±1.24 ^a	95.12±1.87 ^a	96.44±1.17 ^a
T.P (g/dL)	5.59±0.15 ^b	4.83±0.21 ^a	4.47±0.11 ^a	4.67±0.23 ^a
ALB (g/dL)	2.10±0.06 ^a	2.40±0.10 ^b	2.98±0.09 ^c	2.64±0.07 ^{ab}
GLB (g/dL)	3.49±0.13 ^c	2.43±0.11 ^b	1.49±0.17 ^a	2.41±0.20 ^b
TBIL (mg/dL)	2.12±0.02 ^b	1.65±0.14 ^a	1.74±0.19 ^{ab}	1.93±0.19 ^{ab}
DBIL (mg/dL)	1.11±0.29 ^a	0.81±0.12 ^a	0.60±0.07 ^a	1.16±0.28 ^a
InDBIL(mg/dL)	1.01±0.30 ^a	0.83±0.16 ^a	1.14±0.23 ^a	0.77±0.44 ^a
Urea (mg/dL)	25.23±1.01 ^a	24.43±1.44 ^a	27.02±2.74 ^{ab}	32.70±2.77 ^b
Creat.(mg/dL)	0.88±0.03 ^a	0.88±0.04 ^a	0.88±0.02 ^a	0.94±0.01 ^a

Values are Mean±S.E.M, n=5. Values with different superscripts on the same row are significantly different ($p < 0.05$). AST – Aspartate amino transferase, ALT-Alanine aminotransferase, ALP-Alkaline phosphatase, T.P-Total protein, ALB-Albumin, GLB-Globulin, TBIL-Total bilirubin, DBIL-Direct bilirubin, InDBIL-Indirect bilirubin.

The result showed no significant ($p > 0.05$) difference between the extract treated and control groups in the values of creatinine observed.

Effect of methanol extract of *B. africana* stem bark administration on oxidative stress markers of rats

At day 28, Malondialdehyde (MDA) concentration significantly ($p < 0.05$) increased in the extract treated groups when compared with the control group. Catalase activity also increased significantly ($p < 0.05$) in all extract treated groups when compared with the control group. Glutathione (GSH) on the other hand was observed to be significantly ($p < 0.05$) lowered in

animals treated 100 and 200 mg/kg of the extract, while those that were administered the extract at the dose rate of 400 mg/kg showed significantly ($p < 0.05$) increased GSH when compared with the control group (Table 4).

Histopathological changes in some visceral organs

Histopathological examination of the liver of rats treated with methanol extract of *B. africana* stem bark for 28 days, revealed normal morphology of the hepatocytes at all doses (Green arrows), with moderate infiltration of inflammatory cells at the sinusoids and periportal area.

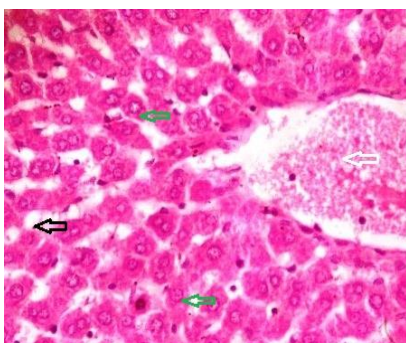


Plate 1: Liver of normal control rats.

Liver section showing normal architecture. Normal central venules (White arrow), normal hepatocytes (Green arrow), normal sinusoids (Black arrow) (H & E X400).

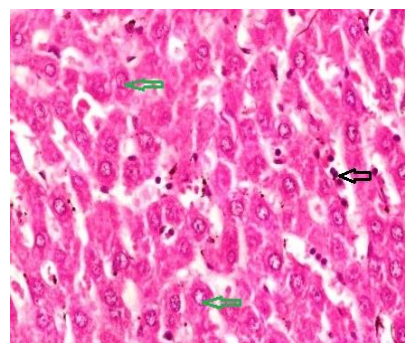


Plate 2: Liver of rats treated with methanol extract of *B. africana* stem bark (100 mg/kg).

Liver section showing the normal morphology of the hepatocytes (Green arrow), sinusoids showing moderate infiltration of inflammatory cell (Black arrow) (H & E X400).

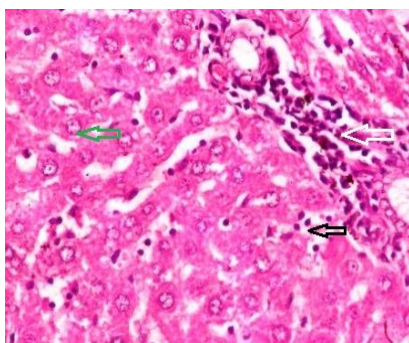


Plate 3: Liver of rats treated with methanol extract of *B. africana* stem bark (200 mg/kg).

Liver section showing moderate periportal infiltration of inflammatory cells (White arrow), normal hepatocytes (Green arrow) and the sinusoids mildly infiltrated by inflammatory cell (Black arrow) (H & E X400).

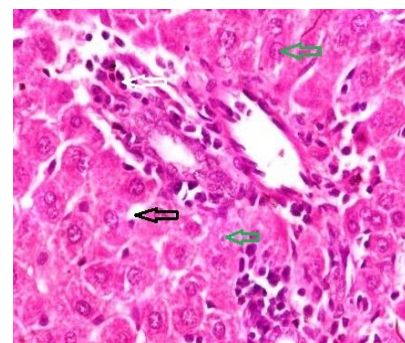


Plate 4: Liver of rats treated with methanol extract of *B. africana* stem bark (400 mg/kg).

Liver section showing moderate periportal infiltration of inflammatory cells (White arrow), hepatocytes appearing normal (Green arrow) and normal sinusoids (Black arrow) (H & E X400).

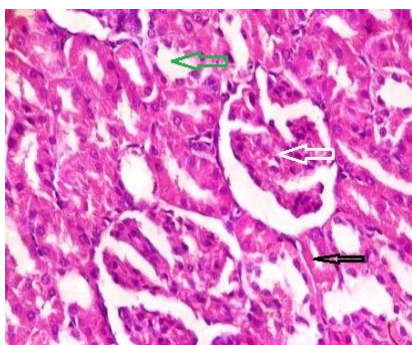


Plate 5: Kidney of normal control rats.

Kidney section showing normal architecture, the renal cortex show normal glomeruli, normal mesangial cells and capsular spaces (White arrow), the renal tubules, Distal and Proximal convoluted tubules appearing normal, (Green arrow) and normal interstitial spaces (Black arrow) (H & E X400).

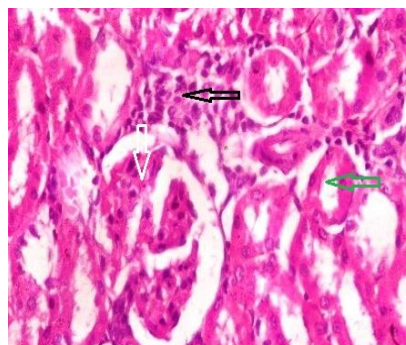


Plate 6: Kidney of rats treated with methanol extract of *B. africana* stem bark (100 mg/kg).

The renal cortex shows normal glomeruli, normal mesangial cells and capsular spaces (White arrow), normal renal tubules, Distal and Proximal convoluted tubules (Green arrow), the interstitial spaces showing focal areas of Inflammatory cells (Black arrow) (H & E X400).

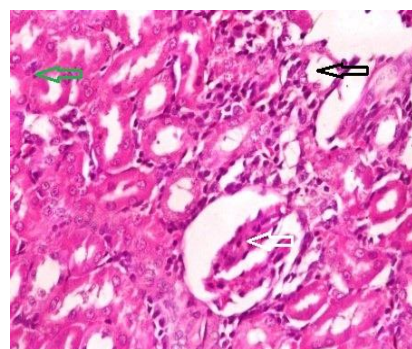


Plate 7: Kidney of rats treated with methanol extract of *B. africana* stem bark (200 mg/kg).

The renal cortex showing normal glomeruli, normal mesangial cells and capsular spaces (White arrow), Normal renal tubules, and convoluted tubules (Green arrow), the interstitial Spaces mildly infiltrated with inflammatory cells (Black arrow) (H & E X400).

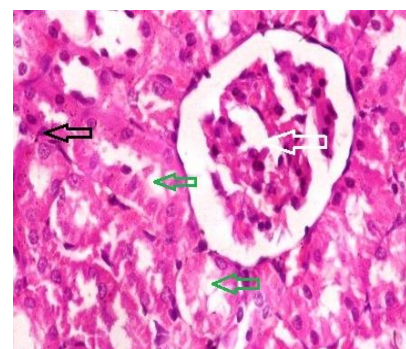


Plate 8: Kidney of rats treated with methanol extract of *B. africana* stem bark (400 mg/kg).

The renal cortex shows normal glomeruli, normal mesangial cells and capsular spaces (White arrow), normal renal tubules Distal and Proximal convoluted tubules (Green arrow), normal interstitial spaces (Black arrow) (H & E X400).

Table 4: Oxidative stress markers of rats treated with methanol stem bark extract of *B. africana* for 28 days.

Groups	MDA (mg/mL)	Catalase (IU/L)	GSH (mg/dL)
Control	2.24±0.06 ^a	8.30±0.19 ^a	2.27±0.05 ^b
100 mg/kg	3.58±0.08 ^b	12.03±0.29 ^b	1.66±0.11 ^a
200 mg/kg	3.60±0.12 ^b	20.61±0.41 ^c	1.75±0.09 ^a
400 mg/kg	3.77±0.13 ^b	25.62±0.73 ^d	2.58±0.05 ^c

Values are Mean±S.E.M, n = 5. Values with different superscripts on the same column are significantly different ($p < 0.05$). MDA- Malondialdehyde, GSH-Glutathione.

The hepatocytes of rats treated with the extract at the dose of 400 mg/kg body weight appeared to have hypochromic nuclei (Green arrow on Plate 4). The liver of control rats showed normal central venules with the characteristic morphology of the hepatocytes and sinusoids (Plate 1). The renal cortex also showed normal glomeruli with normal mesangial cells and capsular spaces (Plate 1). The renal tubules, including distal convoluted and proximal convoluted tubules appeared normal with normal interstitial spaces. At the doses 100 mg/kg and 200 mg/kg, the interstitial spaces showed areas of mild infiltration of inflammatory cells (Black arrows on Plate 6 and Plate 7).

DISCUSSION

The presence of antioxidants such as phenols and flavonoids, saponins, tannins and terpenoids in the methanol stem bark extract of *B. africana* suggests its

anti-oxidative stress potential. There are many reports on the antioxidant, antimicrobial, anti-inflammatory, anti-angiogenic, analgesic, anti-allergic, cytostatic and properties of these phytochemicals suggesting wide range of biological activities^{7,12}. The GC-MS result revealed the presence of (2H) pyrrole-2-carbonitrile, 5-amino-3, 4-dihydro-, an alkaloid and 9, 17-octadecadienal, (Z)-, an unsaturated aldehyde which has been found to have antimicrobial and anti-inflammatory activities^{29,17}. This probably explains the findings of Tor-anyiin and Anyam¹², and Musa *et al.*,⁷. Resorcinol, a phenolic compound is a known antioxidant with hepatoprotective activity⁹ This corroborates a report by Cordier *et al.*,⁹ that the plant is rich in phenol, making it a potent antioxidant. Oleic acid which is also a fatty acid has been proven to be a potent antihypertensive and is found to be in abundance in olive oil³⁰. Wei *et al.*,³¹ also discovered that oleic acid present in *Michelia champaca* flower

may also be responsible for the antimicrobial properties of the plant. This further agrees with the antibacterial, antifungal, larvicidal, molluscicidal¹² and anti-influenza¹⁰ activities of this plant. Knowledge of the possible toxic or adverse effects of many medicinal plants is grossly inadequate. In evaluating the safety status of medicinal plant, acute, sub acute and sometimes chronic toxicity studies are carried out in laboratory animals². In this study, daily oral administration of methanol extract of *B. africana* stem bark at the doses of 100, 200 and 400 mg/kg body weight for 28 consecutive days did not cause any change in behavior or mortality in treated rats, suggesting that the extract is relatively safe. Sign of toxicity such as sedation, lethargy, anorexia, drowsiness and ultimately death have been used to evaluate toxic effect of chemicals and natural medicinal plant products used in traditional medicine by scientists. The absence of these signs is used as a criterion to support that the plant extract is safe for use medicinally³². There was no significant ($P < 0.05$) effect on the body weight and organ-somatic index of the treated rats compared with the normal control (Figure 1 and Figure 2). These findings indicate that the extract showed no adverse effect on the organs (liver, kidney, lungs, heart and spleen) at all doses used in this study and therefore is considered to be safe. Also, the extract maybe said to have no anti-nutritive and growth inhibiting effect since it had no effect on the body weight. According to Unuofin *et al.*,² weight loss of about 10% has been related to an adverse effect. In the same vein, organ-somatic index is often used in toxicological investigations³³⁻³⁵. After 28 days of a single daily oral administration of methanol extract of *B. africana* stem bark, hematological parameters showed some significant changes (Table 2). The fact that the hematopoietic system is readily attacked by toxic substances makes it imperative to always evaluate hematological parameters in toxicity studies to monitor the physiologic and pathological state of animals and humans². The PCV and RBC count of treated groups increased significantly in a dose-dependent manner, with no significant effect on hemoglobin. Hemoglobin, MCH and MCHC remained unaffected, with significant ($p < 0.05$) increase in MCV of treated groups at all doses. Circulating blood carries oxygen, nutrients and foreign substances, making it prone to toxic attacks leading to damages in RBCs, WBCs, platelets and hemoglobin. This gives rise to various forms of anemia depending on the component of the RBC affected and nature of the effect and also immune system failure². The results of this study suggests that the extract probably has stimulatory effect on erythropoiesis and hence useful in the treatment of anemia. The decreases in Leucocytes at 200 and 400 mg/kg, neutrophils at 100 mg/kg, and lymphocytes at 400 mg/kg body weight observed could be due to immunosuppressive potential of the extract. These changes may also be due to inflammatory response and/or stress³⁶. The enzymes (AST and ALT) activities are often used to evaluate the functional status of the liver and the condition of the hepatocytes due to the high amount of these transaminases found in the hepatocytes^{37,38}. However,

ALT is considered more specific to liver³⁷⁻³⁹. Treatments with this extract significantly decreased ($p < 0.05$) the serum activities of ALT after 28 days of oral administration, with no effect on AST and ALP. This suggests the absence of hazardous effect of the extract on the liver. The decrease in serum total protein observed could be due to decrease in globulin. This may be thought to be from the effect of some components of the extract on lymphoid organs with possibility of liver involvement^{37,40}. Albumin increased significantly when rats were treated with extract at 100 and 200 mg/kg. Studies have shown that albumin concentration and function in liver cirrhosis is often reduced⁴¹, which further corroborate with our earlier suggestion that the extract has no adverse effect on the liver. The extract at 100 mg/kg slightly increased total bilirubin, whereas direct (conjugated) and indirect (unconjugated) bilirubin remained unaffected (Table 5), suggesting that there is no problem with bilirubin conjugation in the liver. Hemoglobin metabolism which takes place in the liver, spleen and bone is the major source of bilirubin in the serum³. Elevated serum bilirubin is due to increased destruction of erythrocytes resulting to increased release of hemoglobin as well as obstructive liver disorders^{34,37}. The extract may be said to have bile ducts obstructing tendencies, which is one of the major causes of increased serum bilirubin³⁷. This also is in doubt considering the fact that ALP was consistently unaltered throughout the period of treatment at all doses used in this study.

Urea and creatinine are used to evaluate the functional status of the kidney, although serum creatinine concentration is considered a more reliable marker for evaluation of kidney function^{37,42}. The kidney as an excretory organ, is prone to toxic attack. This toxic effect on the kidney often result in impaired renal functions such as impaired excretion of metabolic waste, maintenance of fluid and electrolyte balance, and hormonal imbalance due to impaired synthesis of such hormones (erythropoietin)³. Serum urea and creatinine concentrations increase due to inability of the kidney to excrete urea and creatinine proportionately to their formation^{3,37}. Daily treatment with methanol stem bark extract of *B. africana* showed serum urea levels to be elevated at 400 mg/kg b. wt. Elevated MDA and decreases in GSH (Table 8) observed is an indication that the crude extract enhances lipid peroxidation and free radical formation when administered for a long period³⁷. Malondialdehyde (MDA) is end result of lipid peroxidation due to increased free radical production or decrease in antioxidant defense system⁴³⁻⁴⁵. Reduced glutathione is a natural antioxidant in the liver and serves to conjugate with toxic metabolite, making them more polar and readily excreted⁴⁵. Therefore the ability of cells to sustain GSH concentration is useful for cell function and survival⁴⁶. Cereser *et al.*,⁴⁶ postulated that low GSH with corresponding decrease in glutathione reductase enzyme (GR) creates an oxidative imbalance, inspiring oxidative processes and then cell death. Reduction in GSH is marked by increase lipid peroxidation caused by free radical reaction seen as increased MDA⁴⁶. The significant ($p < 0.05$) decrease in

GSH in the treated group at the doses used in this study suggest that the extract may have inhibitory effect on the enzyme glutathione reductase which reduces oxidized glutathione (GSSH) thereby depleting reduced Glutathione (GSH). This explains the increased MDA observed in this study. Decrease in catalase activity in serum can be due to imbalance in its utilization and synthesis or as a problem with expression in the gene controlling its synthesis, resulting in oxidative stress and tissue damage induced by precursors of oxidation (pro-oxidants)⁹. This is an indication that the extract has some stimulatory effect on catalase activity and release which further explains the antioxidant properties of this plant in spite of the increased lipid peroxidation and decrease in GSH. Catalase is a very potent antioxidant enzyme in cells and a molecule of catalase can neutralize millions of peroxide molecules to water and oxygen in seconds⁴⁷. Pathological changes in the parenchymal cells of the liver are often associated with changes in serum activities of liver enzymes⁴⁸. Absence of necrosis of the hepatocyte in the treated groups further agrees with the results of the enzyme assay (Table 3). The mild infiltration of inflammatory cells noticed at the periportal region and in the sinusoid is to be considered none pathologic. The kidney cellular morphology appeared normal, indicating that its functional status may not have been altered by the extract.

CONCLUSIONS

In conclusion, the methanol extract of *B. africana* stem bark administration orally for consecutive 28 days up to a dose of 400 mg/kg body weight had no obvious deleterious effect in rats. The results in this study suggest that the plant is safe for use in treatment of the claimed ailments and therefore supports its use in traditional medicine by rural dwellers. Therefore the use of this plant in treatment is best if used for short durations or at lower doses.

AUTHOR'S CONTRIBUTION

Swem TF: laboratory work. **Aba PE:** designing the experiment, interpreted the data. **Udem SC:** conceived the study, contributed in the design of the experiment. **Ahur VM:** interpreted the clinical chemistry and hematology results. **Gberindyer FA:** data interpretation, formal analysis. All authors revised the article and approved the final version.

ACKNOWLEDGEMENTS

This research was fully funded by Tertiary Education Trust Fund (TET Fund) academic staff sponsorship of the, Benue State, Nigeria. Special acknowledgement to the staff of Department of Veterinary Physiology and Biochemistry of the Federal University of Agriculture Makurdi and Department of Veterinary Physiology and Pharmacology of the University of Nigeria Nsukka.

DATA AVAILABILITY

Data will be made available on reasonable request.

CONFLICT OF INTEREST

No conflict of interest associated with this work.

REFERENCES

- Muthulakshmi A, Jothibai MR, Mohan VR. GC-MS analysis of bioactive components of *Feronia elephantumcorrea* (Rutaceae). J Appl Pharmaceut Sci 2012; 02: 69-74. <https://imsear.searo.who.int/handle/123456789/151116>
- Unuofin JO, Otunola GA, Afolayan AJ. Acute and subacute toxicity of aqueous extract of the tuber of *Kedrostis africana* (L.) Cogn in Wistar rats. J Compl Integr Med 2018; 20170139: 1-11. <https://doi.org/10.1515/jcim-2017-0139>
- Abdullah SS. Acute and sub-acute toxicity of *Crataegus aronia* syn. Azarolus (L.) Whole plant aqueous extract in wistar rats. Amer J Pharmacol Toxicol 2011;6: 37-45. <https://doi.org/10.3844/ajtpsp.2011.37.45>
- Agbaire PO, Emudainohwo JOT, Peretiemo-Clarke BO. Phytochemical screening and toxicity studies on the leaves of *Manniophyton fulvum*. Int J of Plant Enveron Sci 2013;3: 1-6.
- NonyaneF, Masupa T. *B. africana* Hook.
- Maroyi A. *B. africana* Hook. Lemmens RHMJ, Louppe D, Oteng-Amoako AA (eds) [Internet] Plant Resource of Trop. Afr.2010 [Cited 2018 Oct. 26], Record from PROTA4U.
- Musa AO, Habatullah KU, Irisim T, Amina BO, Abubakar BA, Hadiza B. Analgesic and anti-inflammatory studies of methanol extract of *B. africana* stem bark Hook (Fabaceae). Trop J Nat Prod Res 2018; 2: 375-379. <https://doi.org/10.26538/tjnpr/v2i8.1>
- Diallo D, Marston A, Terreaux C, Toure Y, Paulsen BS, Hostettmann K. Screening of Malian medicinal plants for antifungal, larvicidal, molluscidal, antioxidant and radical scavenging activities. Phytother 2001; 15:401-406. <https://doi.org/10.1002/ptr.738>
- Cordier W, Gulumian M, Cromarty AD, Steenkamp V. Attenuation of oxidative stress in U937 cells by polyphenolic-rich bark fractions of *B. africana* and *Syzygium cordatum*. BMC Compl and Alter Med 2013; 116: 1-12. <https://doi.org/10.1186/1472-6882-13-116>
- Malterud KE. Ethnopharmacology, chemistry and biological properties of four Malian medicinal plants. Plants 2017; 11: 1-13. <https://doi.org/10.3390/plants6010011>
- Tanko Y, Iliya B, Mohammed A, Mahdi MA, Musa KY. Modulatory effect of ethanol stem bark extract of *B. africana* on castrol oil induced diarrhoeal on experimental animals. Arch of Appl Sci Res 2011;3: 122-130.
- Tor-Anyiin AT, Anyam VJ. Phytochemical evaluation and antibacterial activity: A comparison of various extracts from some Nigerian trees. Peak J Med Plant Res 2013;1: 13-18.
- Natural Research Council of the National Academies (US). Guide for the Care and Use of Laboratory Animals: Committee for the Update of the Guide for the Care and Use of Laboratory Animals Institute for Laboratory Animal Research Division on Earth and Life Studies. (8th Ed). The National Academies press, Washington, D.C. 2011:1-213. <https://doi.org/10.17226/12910>
- Trease GE and Evans WC. Textbook of pharmacognosy. 3rd ed. Bailliere Tindal, London. 1989; 493-508. <https://doi.org/10.1111/j.2042-7158.1949.tb12463.x>
- Sofowora EA. Medicinal Plants and Traditional Medicine in Africa. 2nd ed. England, John and Wiley and Sons Ltd.1993; 55-62. <https://doi.org/10.5772/intechopen.80348>

16. Sofowora EA. Medicinal Plant and Traditional Medicine in Africa. 1st ed. University of Ife Press, Nigeria. 1994; 1-23. <https://doi.org/10.1089/acm.1996.2.365>
17. Adeyemi MA, Ekunseitan DA, Abiola SS, Dipeolu MA, Egbeyale LT, Sogunle OM. Phytochemical analysis and GC-MS determination of *Lagenaria breviflora* R. Fruit. Int J Pharmacog Phytochem Res 2017;9: 1045-1050. <https://doi.org/10.25258/phyto.v9i07.11178>
18. Cheesbrough M. Haematological tests. In: District laboratory practice in tropical countries Part 2, 2nd ed. Cambridge University Press, Cambridge, UK. 2006; 268-347.
19. Thomas L. Clinical Laboratory Diagnostics. 1st ed. Frankfurt: TH-Books Verlags Gesell chaft. 1998; 652-656. <https://doi.org/10.1093/clinchem%2F45.4.586a>
20. Moss DW and Henderson AR. Clinical enzymology. In: Burtis CA, Ashwood ER, (eds.) Tietz Textbook of Clinical Chemistry. 3rd ed. W.B. Saunders Company, Philadelphia. 1999; 617-721. <https://doi.org/10.1007/s12291-012-0287-7>
21. Johnson AM, Rohlfs EM, Silverman LM. Proteins. In: Burtis CA & Ashwood ER (eds.) Tietz textbook of clinical chemistry. 3rd ed. W.B. Saunders Company, Philadelphia. 1999; 447-540. <https://doi.org/10.1046/j.1537-2995.1999.39070794.x>
22. Tietz NW. Fundamentals of Clinical Chemistry. W.B. Saunders Co., Philadelphia. 1976; 1040-1045.
23. Burtis CA, Ashwood ER (eds.) Tietz Textbook of clinical Chemistry, 3rd ed. W.B Saunders Company, Philadelphia. 1999; 1838-1843. <https://doi.org/10.1093/clinchem/45.6.913>
24. Stocks J, Dormandy TL. The autoxidation of human red cell lipids induced by hydrogen peroxide. Brit J Haematol 1971; 20: 95-111. <https://doi.org/10.1111/j.1365-2141.1971.tb00790.x>
25. Sicinska P, Bukowska B, Pajak A, Koceva-Chyla A, Pietras T, Nizinkowski P. Decreased activity of butyryl cholinesterase in blood plasma of patients with chronic obstructive pulmonary disease. Arch of Med Sci 2017;13: 645-51. <https://doi.org/10.5114%2Faooms.2016.60760>
26. Góth L. A simple method for determination of serum catalase activity and revision of reference range. Clin Chim Acta 1991;196: 143-152. [https://doi.org/10.1016/0009-8981\(91\)90067-m](https://doi.org/10.1016/0009-8981(91)90067-m)
27. Moron MS, De Pierre JW, Mannervik B. Levels of glutathione, glutathione reductase and glutathione S-transferase activities in rat lung and liver. Biochim et Biophys Acta 1979;582: 67-68. [https://doi.org/10.1016/0304-4165\(79\)90289-7](https://doi.org/10.1016/0304-4165(79)90289-7)
28. Drury RA, Wallington A, Cameroun SR. Carleton's Histological Techniques. Oxford University Press, New York. 1967; 120-234. *PMCID: PMC2385117*
29. Janakiraman N, Johnson M, Sahaya SS. GC-MS analysis of bioactive constituents of *Peristrophe bicalyculata* (Retz.) Nees. (Acanthaceae). Asian Pac J Trop Biomed 2012; 2(1Suppl): 46-49. [https://doi.org/10.1016/S2221-1691\(12\)60128-2](https://doi.org/10.1016/S2221-1691(12)60128-2)
30. Lopez-Huertas E. Health effects of oleic acid and long chain omega-3 fatty acids (EPA and DHA) enriched milks. A review of intervention studies. Pharmacol Res 2010;61: 200-207. <https://doi.org/10.1016/j.phrs.2009.10.007>
31. Wei LS, Wee W, Siong JYF, Syamsumir DF. Characterization of antimicrobial, antioxidant, anticancer property and chemical composition of *Michelia champaca* seed and flower extracts. Stamford J Pharmaceut Sci 2011; 4: 19-24. <https://doi.org/10.3329/sjps.v4i1.8862>
32. Mohamed AEHH, El-Sayed MA, Hegazy ME, Helaly SE, Esmail AM, Mohamed NS. Chemical constituents and biological activities of *Artemisia herba-alba*. Records of Nat Prod 2010; 4: 1-25.
33. Tahraoui A, El-Hilaly J, Israili ZH, Lyoussi B. Ethnopharmacological survey of plants used in the traditional treatment of hypertension and diabetes in south-eastern Morocco (Errachidia province). J Ethnopharmacol 2007; 100: 105-117. <https://doi.org/10.1016/j.jep.2006.09.011>
34. Arsad SS, Mohd EN, Hamzah H, Othman F. Evaluation of acute, subacute and subchronic oral toxicity of *Rhaphidophora decursiva* (Roxb.) Schott extract in male Sprague Dawley rats. J Med Plant Res 2013;7: 3030-3040. <https://doi.org/10.5897/JMPR2013.2611>
35. Balogun SO, Da Silva IF, Colodel EM, De Oliveira RG, Ascencio SD, Martins DT. Toxicological evaluation of hydro-ethanolic extract of *Helicteres sacarolha* A. J Ethnopharmacol 2013; 157: 285-91. <https://doi.org/10.1016/j.jep.2014.09.013>
36. Weiss DJ, Wardrop KJ (eds.). Schalm's veterinary hematology. 6th ed. Wiley-Blackwell: A John Wiley & Sons Limited Publication, Iowa, USA, 2010; 200-250. <https://doi.org/10.1111/j.1939-165X.2011.00324.x>
37. Ezeja MI, Anaga AO, Asuzu IU. Acute and sub-chronic toxicity profile of methanol leaf extract of *Gouania longipetala* in rats. J Ethnopharmacol 2014;151: 1155-1164. <https://doi.org/10.1016/j.jep.2013.12.034>
38. Uddin N, Hasan MR, Hasan MM, Hossain MM, Alam MR. Assessment of toxic effects of the methanol extract of *Citrus macroptera* Montr. Fruit via biochemical and hematological evaluation in female sprague-dawley rats. Plos One 2014; 9. <https://doi.org/10.1371/journal.pone.0111101>
39. Ramaiah SK. Preclinical safety assessment. Current gaps, challenges and approaches in identifying translatable biomarkers of drug- induced liver damage. Clin Lab Med 2011; 31: 161-172. <https://doi.org/10.1016/j.cll.2010.10.004>
40. Donga S, Shukia VJ, Ravishankar B, Ashok BK, Mishtry IU. Chronic toxicity study of *Butea mosperma* (Linn) Kuntze seeds in albino rats. Ayur 2011; 32: 120-125. <https://doi.org/10.4103/0974-8520.85743>
41. Garcia-Martinez R, Caraceni P, Bernardi M, Gines P, Arroyo V. Albumin: pathophysiologic basis of its role in the treatment of cirrhosis and its complications. Hepatol 2013; 58: 1836-1846. <https://doi.org/10.1002/hep.26338>
42. Mukinda JT, Eagles FK. Acute and sub-chronic oral toxicity profile of the aqueous extract of *Pohy gala fruticosa* in female mice and rats. J Ethnopharmacol 2010; 128: 236-240. <https://doi.org/10.1016/j.jep.2010.01.022>
43. Kandhare AD, Raygude KS, Ghosh P, Ghule AE, Bodhankar SL. Neuroprotective effect of naringin by modulation of endogenous biomarkers in streptozotocin induced painful diabetic neuropathy. Fitoterapia 2012; 83: 650-659. <https://doi.org/10.1016/j.fitote.2012.01.010>
44. Visnagri A, Kandhare AD, Shiva Kumar V. Elucidation of ameliorative effect of Co-enzyme Q10 in streptozotocin-induced diabetic neuropathic perturbation by modulation of electrophysiological, biochemical and behavioral markers. Biomed Aging Path 2012; 2: 157-172. <https://doi.org/10.1016/j.biomag.2012.10.006>
45. Adil M, Kandhare AD, Ghosh P, Venkata S, Raygude KS, Bodhankar SL. Ameliorative effect of naringin in acetaminophen- induced hepatic and renal toxicity in laboratory rats: role of FXR and KIM-1. Renal Fail 2016; 6049: 2-15. <https://doi.org/10.3109/0886022x.2016.1163998>
46. Cereser C, Sophie B, Parviz P, Andre´ R. Thiram-induced cytotoxicity is accompanied by a rapid and drastic oxidation of reduced glutathione with consecutive lipid peroxidation and cell death. Toxicol 2001; 163: 153-162. [https://doi.org/10.1016/s0300-483x\(01\)00401-2](https://doi.org/10.1016/s0300-483x(01)00401-2)
47. Sen S, Chakraborty R. The role of antioxidants in human health. Oxidative Stress: Diagnosis, Prev Ther 2011; 1083: 1-37. <https://doi.org/10.1021/bk-2011-1083.ch001>
48. Okoye TC, Akah PA, Ezike AC, et al. Evaluation of the acute and sub-acute toxicity of *Annona senegalensis* root bark extracts. Asian Pac J Trop Med 2012; 5: 277-282. [https://doi.org/10.1016/S1995-7645\(12\)60039-X](https://doi.org/10.1016/S1995-7645(12)60039-X)